

CLINICAL EFFICACY OF VARIOUS ORAL WOUND DRESSING MATERIALS; A SYSTEMATIC REVIEW

Suhael Ahmed^{1*}, Elham Yaqub², Alghalia Almalik², Malak Aljuhani², Rawan Alrrashod²

1. Department of Oral and Maxillofacial Surgery, Riyadh Elm University, Riyadh, Saudi Arabia.
2. Department of Dentistry, Riyadh Elm University, Riyadh, Saudi Arabia.

ARTICLE INFO

Received:
23 Jul 2022
Received in revised form:
18 Oct 2022
Accepted:
22 Oct 2022
Available online:
28 Oct 2022

Keywords: BIPP, ZOE, Alvogyl, Intraoral wound dressing

ABSTRACT

For wounds, discomfort, infection, and healing, there are a limited number of medications used in oral and maxillofacial surgery. Despite their widespread use, little is known about these medications' components, applications, and effects on oral tissues. Whitehead's varnish (WV), Carnoy's solution (CS), Bismuth Iodoform Paraffin paste (BIPP), Zinc Oxide Eugenol (ZOE), Alvogyl are some of the substances that can be used effectively. A systematic literature review from 2012 to 2022 will be performed using databases such as PubMed, Medline, and Scencedirect. The keywords used will be "BIPP", "ZOE", "Alvogyl" and "intraoral wound dressing". PRISMA flowchart will be used to describe the selection process of searched articles. Mixed findings have been observed especially when choosing between ZOE and Alvogyl as an intraoral wound dressing material. Each of these two materials possesses suitable qualities. However, BIPP has not been witnessed to be used frequently due to its potential for side effects when used for longer durations. Alvogyl and Zinc Oxide Eugenol are equally acceptable materials of choice for use as intraoral dressing.

This is an *open-access* article distributed under the terms of the *Creative Commons Attribution-Non Commercial-Share Alike 4.0 License*, which allows others to remix, tweak, and build upon the work non commercially, as long as the author is credited and the new creations are licensed under the identical terms.

To Cite This Article: Ahmed S, Yaqub E, Almalik A, Aljuhani M, Alrrashod R. Clinical Efficacy of Various Oral Wound Dressing Materials; A Systematic Review. *Pharmacophore*. 2022;13(5):99-104. <https://doi.org/10.51847/EdD51jvEYI>

Introduction

Dressings for wounds have been used for centuries to clean, cover, and protect wounds from foreign threats. A wound dressing's objective is to keep the wound clean and free of pathogenic microorganisms while also allowing for optimal healing. It is vital that dressings can be removed without causing additional harm to the wound surface during dressing changes [1].

The location of the site, the type of wound, the presence or risk of infection, and the duration of the wound all factor into the wound dressing selection process. A hydrocolloid or semipermeable film covering is frequently used to heal abrasions due to the limited amount of fluid produced by wounds. In partial-thickness wounds such as burns, donor sites, and superficial traumatic injuries, as well as in some surgical wounds, foam gauze or hydrocolloid dressings can be utilized to expedite healing rates. Additionally, they alleviate discomfort and enhance overall well-being [2].

For wounds, discomfort, infection, and healing, there are a limited number of medications used in oral and maxillofacial surgery [3-5]. Despite their widespread use, little is known about these medications' components, applications, and effects on oral tissues. Whitehead's varnish (WV), Carnoy's solution (CS), Bismuth Iodoform Paraffin paste (BIPP), Zinc Oxide Eugenol (ZOE), Alvogyl are some of the substances that can be used effectively [6, 7].

Fractures and open wounds can be bandaged with BIPP. Dry sockets can be prevented by using this product [8]. Rutherford Morison was the first to report a paste made of bismuth iodide and paraffin (BIPP). With the addition of bismuth and iodoform to paraffin, wounds heal more quickly and are less prone to infection. When bullets and huge open wounds were commonplace during World War I, this discovery was produced because of the urgency of the situation. Tri iodomethane, often known as iodoform, is a chemical compound with the formula CHI₃.

As far as Alvogyl is concerned, alveolar osteitis is the most prevalent condition for this drug. However, butamben, scientifically known as butyl 4-aminobenzoate, is an ester anesthetic used topically. Iodoform is an iodine-based

Corresponding Author: Suhael Ahmed; Department of Oral and Maxillofacial Surgery, Riyadh Elm University, Riyadh, Saudi Arabia. E-mail: Suhael.ahmed@riyadh.edu.sa

antibacterial agent. This paste-like consistency is achieved by mixing a large number of different compounds with the active ingredients already mentioned (**Figure 1**). This table lists Alvogyl's manufacturer-supplied composition. Researchers discovered that Alvogyl slowed the healing of extraction sockets [9, 10].



Figure 1. Alvogyl

A single Alvogyl extraction socket was treated; the other was left untreated each extraction site was sampled at one week and two weeks after extraction to compare healing rates. The Alvogyl treatment resulted in a considerable increase in fibrous tissue, inflammatory reaction, and large cells, as the researchers discovered. Patients found Alvogyl-treated areas less painful than those that weren't. Recently, Kaya *et al.* proved the efficiency of alvogyl in the treatment of alveolar osteitis in the Journal of American Medical Association. An aloe vera extract called Alvogyl and low-level laser therapy is used to treat burns. They compared the two treatments. When compared to curettage alone, all interventions reduced discomfort significantly [11, 12].

Zinc oxide and eugenol-based dressings have known that Eugenol and its derivatives have beneficial properties and are hence used to induce anesthesia in the past. It is important to note that zinc oxide compounds are not antibacterial. As a paste or cement, Zinc oxide can be utilized to cover gingival tissue and extraction sockets. Food and other things are physically prevented from passing through these materials [13].

Eugenol-containing and Eugenol-free components can be found in a variety of products (**Table 1**). Derivatives of the chemical eugenol have been used to induce general anesthesia in clinical trials. Postoperative discomfort is often alleviated by having these features when there is inflammation. This chemical has been related to cytotoxicity in high levels, whereas contact allergy has been linked to low doses.

Table 1. Zinc oxide containing different material

Eugenol-containing	Non-eugenol-containing
Kalzinol	Coe-Pak
Novitec	Perio Care

This dry socket case was recorded by Alemen Navas *et al.* (2010), who used a zinc oxide and eugenol treatment 2010 [14]. When it was left in the alveolus, it caused excruciating pain [14]. These bandages have to be removed before the procedure can begin. Products that do not contain eugenol zinc oxide eliminates the danger of cytotoxicity and allergies.

The Rationale of the Study

The findings of this systematic review will help oral surgeons to make better decision making when choosing wound dressing materials.

Study Hypotheses

BIPP has superior qualities as compared to ZOE and Alvogyl when it comes to an intraoral wound dressing.

Aims of the Study

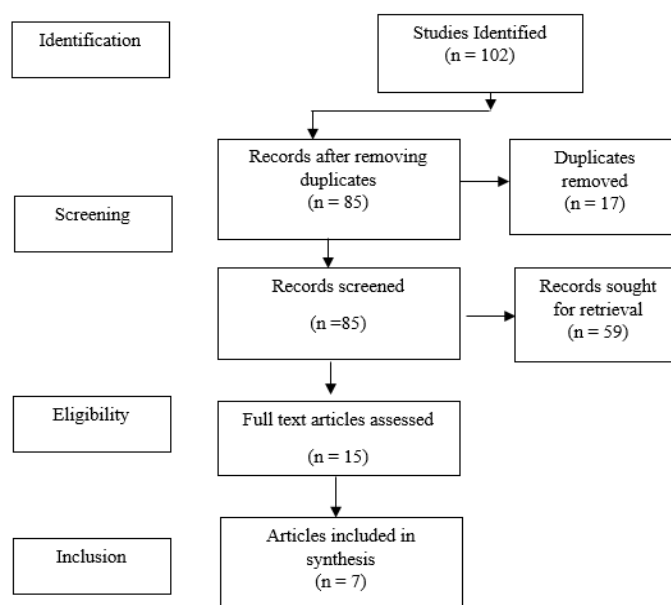
This study aims to determine the best material of choice for intraoral wound dressing.

Materials and Methods

A systematic literature review from 2012 to 2022 was performed using databases such as PubMed, Medline, and Sciondirect. The keywords used were "BIPP", "ZOE", "Alvogyl" and "intraoral wound dressing" (**Table 2**). PRISMA flowchart was used to describe the selection process of searched articles (**Figure 2**).

Table 2. Inclusion and exclusion criteria

No	Inclusion criteria	Exclusion criteria
1.	Case-control and randomized control studies, case reports, and case series.	Systematic reviews or meta-analyses or expert opinions or narrative reviews
2.	Published between 2012 and 2022	Out of the specified time range
3.	Studies including BIPP, ZOE and Alvogyl.	Studies with treatment options other than these three dressing materials.
4.	English language of publication	Language other than English
7.	In vivo (humans)	In vitro

**Figure 2.** PRISMA Flow Diagram

Risk of Bias Assessment

The Cochrane risk of bias assessment method was used to assess the quality of the studies included (Table 3).

Table 3. Summary of Cochrane Risk of Bias Assessment

Study	Selection Bias/Appropriate control selection/baseline characteristics similarity	Selection bias in randomization	Selection bias in allocation concealment	Performance-related bias in blinding	Reporting bias/Selective reporting of outcomes	Detection bias Blinding outcome assessors	Accounting for confounding bias
Atwal & Cousin (2015) [15]	+	+	-	+	+	+	+
Agrawal <i>et al.</i> , (2014) [16]	+	+	-	+	+	+	+
Charlu <i>et al.</i> , (2018) [17]	+	+	+	-	+	+	+
Chaurasia <i>et al.</i> , (2017) [18]	+	+	+	+	+	+	-
Faizel <i>et al.</i> , (2014) [19]	+	+	+	+	+	-	+
Supe <i>et al.</i> , (2018) [20]	+	+	+	-	+	+	+
Khalifah (2018)	+	-	+	+	+	+	-

Results and Discussion

Atwal & Cousin (2015) characteristic features of Bismuth iodoform paraffin packs when used as a wound dressing material [15]. They revealed that reactions to BIPP packs are uncommon but well-known. The most frequent is a type IV hypersensitivity response (pain, itching, rash) to iodoform, which takes place in 2% of patients on primary exposure, and in up to 10.9% of patients on repeat use. Many cases of bismuth toxicity have been documented. Although bismuth could seep

into saliva that was swallowed, poor absorption from the gut advocated that it had been absorbed hematogenous over the wide area of raw cancellous bone that was visible within the cystic cavity.

Agrawal *et al.*, (2014) reported that Bismuth has topical antiseptic features and can be employed as an astringent [16]. This property endorses the antibacterial characteristics of BIPP by discharging dilute nitric acid on hydrolysis. Bismuth has side effects such as neurotoxicity because it is famous to impede with oxidative metabolism of the brain. Symptoms of its toxicity comprise headaches, nausea, and Stomatitis. With the prolonged and careful follow-up and consumption of BIPP, it is possible to save the patient from a supra-major surgery such as resection of the mandible, free fibular flap, or periodontal surgery. The only disadvantage is the increased likelihood of pathological fracture in the course of the follow-up period. The patient should be recommended a soft diet for a long period. This technique of conservative management using BIPP can be employed in benign lesions, cystic lesions, etc. but not in case of malignancies where a hostile approach remains the treatment of choice.

Charlu *et al.*, (2018) evaluated the qualitative characteristics of BIPPs as intraoral wound dressing agents [17]. The efficacy and practicality of the BIPP dressing were assessed by scoring the subsequent parameters in the intraoperative as well as postoperative times: operability, hemostatic standing, pain relief, feeding state, epithelialization, scar contracture, and biocompatibility. Findings revealed that out of the 10 patients, in six patients BIPP was employed for the buccal mucosal defect, in two patients for labial mucosal defect, and one patient each for tongue and palatal defect. In all the patients the raw wound post-resection was concealed with a BIPP pack and steadied with vicryl sutures. Postoperatively there was no hostile event, there was no distress and all the patients accepted the BIPP dressing. BIPP utilization in covering the post-operative intra-oral wound provided an acceptable outcome [21].

Chaurasia *et al.*, (2017) evaluated the prevalence, and probable risk factors and compare the efficiency of the two most frequently used agents (Zinc oxide eugenol and Alvogyl) for the management of dry sockets [18]. It was discovered that pain scores after 30 minutes, 7 days, and ten days were considerably better in the ZOE group as compared to the Alvogyl group. Therefore it was concluded that ZOE is more useful in the management of dry sockets for early as well as final pain relief compared to Alvogyl. However, the authors recommend additional interventional studies with a bigger sample size to compare the outcome of these materials on the healing of extraction sites.

Another similar study conducted by Faizel *et al.*, (2015) prospectively gauged and compare the success of Alvogyl and Zinc Oxide Eugenol (ZOE) intra-alveolar dressings for the treatment of dry socket and assessed the epidemiological factors connected with the condition [19]. Findings revealed that the onset of pain relief with Alvogyl was quicker but not persistent. ZOE was the most cost-effective and conveniently accessible medicament for dressing. However, intervention is rather introduced immediately upon diagnosis.

Supre *et al.*, (2018) also investigated the effect of ZOE and Alvogyl in the management of dry sockets [20]. This study established that alvogyl is the most effective combination for the treatment of dry sockets. ZOE is a cost-effective and easily accessible medicament for dressing. Even though both the agents exhibited positive outcomes, alvogyl needed a minimum number of dressings and was faster in providing long-term pain relief. Nevertheless, a larger sample size is obligatory to certainly demonstrate that alvogyl is undeniably superior to ZOE despite its cost to practicing dental surgeons. Furthermore, additional research should take into account patients with systemic diseases.

Another interesting study outcome was presented by Khalifah (2021) as he stated that there has been no commonly agreed-on treatment of choice for alveolar osteitis, alvogyl and ZOE were suggested by more than one author [22]. Additionally, until 2014, there were no comparative investigations for two or more materials. However, in this study, ZOE was more successful as compared to alvogyl in mild and moderate cases. However, both agents were unsuccessful for severe and agonizing pain cases.

This systematic review was conducted to compare the effectiveness of various intraoral wound dressing materials including BIPP, ZOE, and Alvogyl. Several studies described the varying properties and use of these materials and it can be noted from the findings above that the most acceptable material of choice includes both ZOE as well as Alvogyl. However, BIPP has not been reported to be used more frequently therefore further studies are required to substantiate its application in commonly occurring intraoral procedures.

It can be perceived from the findings that the side effects of intraoral dressing materials are the key to deciding which agent should be used. As mentioned above, BIPP has exhibited encouraging outcomes, but the unwanted effects related to its use have been a cause of hindrance and lack of use. Relatively smaller numbers of studies have advocated its use as the dressing material for important surgeries such as inflammatory dentigerous cyst removal. BIPP as a dressing material in packing the cystic cavity proved effective with rapid healing of the defect, less patient discomfort, and compatibility to use. Its short-term application showed no systemic or local harmful effects on the patient. However, its prolonged use is still questionable [23, 24].

Apart from the consumption of conventional ZOE in the management of dry sockets some other products have also been used such as viscous 2% lidocaine jelly, clindamycin, Bucco-adhesive metronidazole tablets, or topical metronidazole. However, the treatment of dry sockets in the majority of the clinics remains detailed with irrigation with warm normal saline and a zinc oxide eugenol dressing positioned securely in the extraction socket. The affordability and availability of zinc oxide eugenol as well as the acceptable results achieved appear to have stimulated its repeated use. Additionally, although foreign body response among other conceivable adverse reactions to zinc oxide eugenol has been stated in the literature, its usage is still witnessed to be frequent [25].

When applying the matter of wound healing in patients, it is significant to distinguish both the type of injury with respect to location and form of tissue involved (e.g., periodontium, extraction site, or extensive resection site), as well as the rationale behind the specific type of dressing (e.g., preventing infection, tissue coverage, hemostasis). When the dentist faces one of the circumstances discussed above, caution and carefulness must always be accomplished. This comprises taking note of the patient's medical background and history, as well as suitable documentation of the justification for the method and the intended consequence. The possible difficulties of the anticipated effect should be considered and, if needed, addressed consequently [26].

Future studies need to be conducted which should include all three materials discussed in this study in order to achieve accurate comparisons to help dental surgeons decide.

Conclusion

- Alvogyl and Zinc Oxide Eugenol are equally acceptable materials of choice for use as intraoral dressing.
- Further studies need to be conducted in order to confirm the efficacy and safety of BIPP as a regularly used intraoral wound dressing material.

Acknowledgments: None

Conflict of interest: None

Financial support: None

Ethics statement: This study was cleared by the ethical committee of Riyadh Elm University.

References

1. Bueno J, Demirci F, Baser KH. Antimicrobial strategies in novel drug delivery systems: applications in the treatment of skin and soft tissue infections. In *The Microbiology of Skin, Soft Tissue, Bone and Joint Infections 2017* Jan 1 (pp. 271-286). Academic Press.
2. PS GT, Shetty P, Rai AJ, Gohil SM. Management of abrasions in oral and maxillofacial surgery-a review. *J Health Allied Sci NU*. 2016;6(03):41-4.
3. Samara M, Klimov AE, Persov MY, Kirtadze DG, Barhudarov AA. Justification of the differentiated approach to minimally invasive and open surgeries for acute pancreatitis complications. *Arch Pharm Pract*. 2020;11(2):65-8.
4. Alanazi AY, Al Mubarak AS, Shahatah MA, Banjar RZ, Hassan S. Surgical management of cataract in diabetes mellitus patients. *Arch Pharm Pract*. 2019;10(2):31-4.
5. Alruwaili A, Alosaimi M, Alnahas TM, Alferayan TA, Alsulami GO, Alhulaybi A, et al. Adhesion awareness among Saudi surgeons: a national survey. *Int J Pharm Res Allied Sci*. 2020;9(1):75-83.
6. Randhawa GK, Graham RM, Matharu KS. Bismuth iodoform paraffin paste: history, uses and alternatives in oral and maxillofacial surgery. *Dent Update*. 2021;48(3):207-11.
7. Acharya D, Sethi AK, Mitra M, Taniya K. Comparison between neocone, alvogyl and zinc oxide eugenol packing for the treatment of dry socket. *J Pharm Negat Res*. 2022:794-7.
8. Samson J, Pandurangan P, Balasubramanian A, Jayabalan J. Versatility of buccal pad of fat in the reconstruction of oral and maxillofacial defects--A review. *J Evol Med Dent Sci*. 2021;10(38):3441-6.
9. Muravev NV, Diachkova EY, Larionova EV, Tarasenko SV. Medicinal methods for prevention and treatment of alveolar osteitis. *Ann Dent Spec Vol*. 2021;9(1):16.
10. Ehab K, Abouldahab O, Hassan A, Fawzy El-Sayed KM. Alvogyl and absorbable gelatin sponge as palatal wound dressings following epithelialized free gingival graft harvest: a randomized clinical trial. *Clin Oral Investig*. 2020;24(4):1517-25.
11. Kaya GŞ, Yapıcı G, Savaş Z, Güngörmüş M. Comparison of alvogyl, SaliCept patch, and low-level laser therapy in the management of alveolar osteitis. *J Oral Maxillofac Surg*. 2011;69(6):1571-7.
12. Assari AS, Alrafie HS, Ghashim A, Homoud A, Talic FN, Alahmari AM, et al. Effectiveness of different socket dressing materials on the postoperative pain following tooth extraction: a randomized control trial. *J Med Life*. 2022;15(8).
13. Ku JK, Leem DH. The vestibuloplasty using non-eugenol-based non-zinc oxide oral dressing material. *J Korean Dent Sci*. 2021;14(1):46-50.
14. Alemán Navas RM, Martínez Mendoza MG. Case report: late complication of a dry socket treatment. *Int J Dent*. 2010;2010.
15. Atwal A, Cousin GC. Bismuth toxicity in patients treated with bismuth iodoform paraffin packs. *Br J Oral Maxillofac Surg*. 2016;54(1):111-2.

16. Agrawal R, Sangle A, Vyawahare A. Bismuth iodoform and paraffin paste a boon in treatment of keratocystic odontogenic tumor: a case report. *J Dent Med Res.* 2014;1:32-5.
17. Charlu AP, Kumar S, Chacko R. Qualitative evaluation of BIPP dressing for intraoral mucosal defect. *J Clin Diagnostic Res.* 2018;12(4).
18. Chaurasia NK, Upadhyaya C, Dixit S. Comparative study to determine the efficacy of zinc oxide eugenol and alveogyl in treatment of dry socket. *Kathmandu Univ Med J.* 2017;59(3):203-6.
19. Faizel S, Thomas S, Yuvaraj V, Prabhu S, Tripathi G. Comparison between neocone, alvogyl and zinc oxide eugenol packing for the treatment of dry socket: a double blind randomised control trial. *J Maxillofac Oral Surg.* 2015;14(2):312-20.
20. Supe NB, Choudhary SH, Yamyar SM, Patil KS, Choudhary AK, Kadam VD. Efficacy of alvogyl (combination of iodoform+ butylparaminobenzoate) and zinc oxide eugenol for dry socket. *Ann Maxillofac Surg.* 2018;8(2):193.
21. Joshi S, Steel C, Eyeson J. Alveogyl: foreign body reaction. *dent update.* 2021;48(4):299-301.
22. Khalifah M. Curettage versus Zinc Oxide Eugenol as a Treatment Modality in Patients with Dry Socket. *Egypt Dent J.* 2021;67(1-January (Oral Surgery)):235-9.
23. Morawala A, Shirol D, Chunawala Y, Kanchan N, Kale M. Bismuth subnitrate iodoform paraffin paste used in the management of inflammatory follicular cyst—Report of two cases. *J Indian Soc Pedod Prev Dent.* 2017;35(3):269.
24. Reeshma S, Dain CP. Comparison of platelet-rich fibrin with zinc oxide eugenol in the relief of pain in alveolar osteitis. *Health Sci Rep.* 2021;4(3):e354.
25. Oginni FO, Fatusi OA, Alagbe AO. A clinical evaluation of dry socket in a Nigerian teaching hospital. *J Oral Maxillofac Surg.* 2003;61(8):871-6.
26. Sharon E, Polak D, Sharon S, Beyth N. Wound Dressing in the Oral Cavity. In *Biofilm, Pilonidal Cysts and Sinuses* 2017 (pp. 55-68). Springer, Cham.