

IMPACT OF ENDODONTIC TREATMENT AND CORONAL RESTORATION ON ENDODONTICALLY TREATED TEETH'S PERIAPICAL STATE; A SYSTEMATIC REVIEW

Yousef Saleh AlAnazi^{1*}, Mohammed Abdulrahman Saif AlQahtani², Saeed Ateeq Kh Al Zahrani², Musallam Abdullah AlMusallam², Rajeh Abdullah AlDosari², Mashael Obaid AlShahrani³, Turki Abdullah Al Qarni⁴, Mshari Suliman Al Mutairi², Saeed Ali AlQahtani³

1. Department of Restorative Dentistry, North of Riyadh Dental Center, Ministry of Health, Riyadh, Saudi Arabia.
2. North of Riyadh Dental Centre, Ministry of Health, Riyadh, Saudi Arabia.
3. Department of Endodontics, Riyadh Specialized Dental Center, Ministry of Health, Riyadh, Saudi Arabia.
4. Department of Patient Experience, North of Riyadh Dental Center, Ministry of Health, Riyadh, Saudi Arabia.

ARTICLE INFO

Received:

10 Jul 2022

Received in revised form:

16 Oct 2022

Accepted:

19 Oct 2022

Available online:

28 Oct 2022

Keywords: Coronal restoration, Root canal quality, Periapical status, Systematic review

ABSTRACT

Periapical lesions brought on by pulpal infections are one of the most specialised conditions in dentistry. The main objective of endodontic therapy is to use chemo-mechanical debridement and root canal filling to significantly reduce or eliminate the microbial load within the root canal system. The objectives of root canal therapy are to eliminate microorganisms from the canal system, remove inflammatory and necrotic pulp tissue, and stop the infection from returning. The teeth's function and aesthetics may be restored and maintained if this is accomplished. The success rate of root canal therapy may exceed 90% when carried out to the highest standards and ranges from 75% to 80% when a periapical lesion is present. One of the most specific disorders in the dentistry sector is periapical lesions brought on by pulpal infections. A systematic literature review from 2011 to 2022 was performed using PubMed, Medline, and ScienceDirect databases. The keywords used were "coronal restoration," "root canal quality," and "periapical status." There were a total of eight studies considered, and the vast majority of them supported the notion that the periapical health of the tooth has a substantial correlation with the effectiveness of root canal therapy and coronal restoration. The effectiveness of root canal therapy and coronal restoration and the frequency of periapical issues are significantly correlated. The presence or absence of an apical radiolucency was statistically related to the effectiveness of endodontic therapy and the presence of a coronal restoration.

This is an *open-access* article distributed under the terms of the *Creative Commons Attribution-Non Commercial-Share Alike 4.0 License*, which allows others to remix, tweak, and build upon the work non commercially, as long as the author is credited and the new creations are licensed under the identical terms.

To Cite This Article: AlAnazi YS, AlQahtani MAS, AlZahrani SAKh, AlMusallam MA, AlDosari RA, AlShahrani MO, et al. Impact of Endodontic Treatment and Coronal Restoration on Endodontically Treated Teeth's Periapical State; A Systematic Review. *Pharmacophore*. 2022;13(5):78-85. <https://doi.org/10.51847/VWRGTjjYyO>

Introduction

The objectives of root canal therapy are to eliminate microorganisms from the canal system, remove inflammatory and necrotic pulp tissue, and stop the infection from returning [1-3]. The teeth's function and aesthetics may be restored and maintained if this is accomplished. The success rate of root canal therapy may exceed 90% when carried out to the highest standards and ranges from 75% to 80% when a periapical lesion is present. One of the most specific disorders in the dentistry sector is periapical lesions brought on by pulpal infections. The main objective of endodontic therapy is to completely eradicate or drastically lower the microbial burden within the root canal system by employing chemo-mechanical debridement followed by root canal filling [4].

However, despite technical breakthroughs in root canal treatment techniques, some investigations have revealed that apical

Corresponding Author: Yousef Saleh AlAnazi; Department of Restorative Dentistry, North of Riyadh Dental Center, Ministry of Health, Riyadh, Saudi Arabia. E-mail: L.Oz@hotmail.com

periodontitis is still increasing. As a result, the presence or disappearance of such lesions may be utilized to determine whether endodontic treatment was successful or not [5]. In many regions of the globe, researchers have looked at how often healthy periapical zones coexist with correctly filled root canals. Epidemiological data from these studies showed a range of treatment outcomes, including a prevalence of up to 72.4% inadequate root canal fillings and apical periodontitis in 87.0% of these teeth. Undoubtedly, endodontic therapy's success does not rely exclusively on the caliber of root canal therapy. Along with correctly completed root canal fillings, good quality apical periodontitis healing restorations seems to be a prerequisite for avoiding reinfection and positively influencing it, which increases endodontic success and tooth survival [6].

It is well acknowledged that the technical excellence of root filling correlates favorably with the success of root canal therapy. It is predicted that root canals with adequate filling would provide a three-dimensional barrier against bacterial entry. Under carefully monitored clinical conditions, the probability of a successful primary root canal therapy may exceed 90% in the absence of preoperative apical periodontitis and range from 75% to 80% in the event that it is present. Despite this, epidemiological studies of endodontic therapy performed in various cohorts outside of a university-supported clinical setting revealed less favorable treatment outcomes, with high rates of faulty root fillings and apical periodontitis (40%–65%) associated with teeth that had undergone endodontic treatment. This study clarified the requirement for a coronal seal for the healing of these lesions [7].

Complete debridement, disinfection, and root canal filling (RCF) are crucial to endodontic therapy's success. Recent developments in endodontic treatment have broadened its scope. These include knowledge of anatomy and morphology, a method of diagnosis, and a therapy plan. Endodontic therapy aims to completely seal the apical and coronal regions to prevent the infiltration of microorganisms. However, failure of root canal therapy is often indicated by the development of apical periodontitis at the apex of the tooth. Possible causes include inadequate cleaning during root canal therapy or a failure to seal off the root canal system properly. Coronal leaking has also been associated with treatment failure. Therefore, effective endodontic treatment must minimize coronal leakage and maintain an appropriate seal. Clinical symptoms and x-rays work together to establish the need for root canal therapy (RCT). Healing is indicated by the absence of clinical symptoms and by a radiograph with an intact periodontal ligament space in the apical region [8].

In contrast, apical periodontitis shows that the disease is still active. Two-dimensional periapical radiographs or panoramic radiographs have been widely used in cross-sectional investigations of periapical status (PS) in root canal-treated teeth (RCTT) and coronal seal correlation (2D). However, recent studies have shown that 2D radiography has drawbacks, especially when evaluating treatment efficacy and spotting periapical radiolucency (PR). Cone-beam computed tomography (CBCT) scanning can overcome most of the limitations of 2D radiography. This is because CBCT scanning is very sensitive to identifying bone changes. The prevalence of periapical radiolucency has increased 14-fold, according to a recent clinical study. Numerous studies have supported the significance of coronal leakage as a potential cause of root canal treatment failure [9].

Several criteria for the effectiveness of endodontic treatment are universally acknowledged from a radiographic perspective. The lamina dura is normal; there is no sign of resorption; the recent osseous rarefaction has healed (or at least regressed); the periodontal ligament space is regular (or has only slightly thickened); and there is a dense and homogenous three-dimensional obturation of the root canal system, including a sufficient coronal restoration. To accomplish the aforementioned clinical outcomes, it is also necessary to remove (or at least significantly reduce) all live pathogenic microorganisms from the root canal due to the aetiological influence of microbial infection [10]. Although endodontic treatment has evolved over the last several decades due to technological and procedural advancements, the success rate of root canal therapy has not altered much, as shown by many studies. Therefore, a recent systematic review of observational studies [9] found a weighted mean prevalence of apical periodontitis in root canal-treated teeth of 35.9% (10.2%), indicating a wide range in treatment quality. When the major international studies from the last six years were combined (each with more than 10,000 teeth and a total of about 20,000 root canal-filled teeth), the mean frequencies of apical pathoses came to a comparable pooled average rate of about 33%, demonstrating consistent infection rates of root canal-filled teeth [11].

Epidemiological data demonstrate that treatment outcomes vary around the globe, with a prevalence rate of insufficient root canal fillings reaching up to 72.4% and apical periodontitis in 87.0% of these teeth. In order to establish the frequency of inadequately filled root canals in sound periapical regions, several observational studies [12] were conducted. In actuality, more factors than just the calibre of the root canal procedure contribute to a successful endodontic treatment outcome (and, therefore, a tight coronal and apical seal of the shaped and cleaned root canal). Post-endodontic restorations of sufficient quality appear to be as important as the quality of the root canal fillings in ensuring that the tooth does not become reinfected and in promoting the healing of apical periodontitis, thus increasing the likelihood of endodontic success and tooth survival [13].

Materials and Methods

Aims of the Study

In this study, the effects of root canal therapy and coronal restoration quality were examined in relation to the periapical condition of teeth that had undergone endodontic treatment.

A systematic literature review from 2011 to 2022 was performed using PubMed, Medline, and ScienceDirect databases. The keywords used were "coronal restoration," "root canal quality," and "periapical status." In addition, the PRISMA flowchart

was used to describe the selection process of searched articles.

Table 1. Inclusion and exclusion criteria

N ^o	Inclusion criteria	Exclusion criteria
1.	Case-control and randomized control studies	Systematic reviews or meta-analyses or expert opinions, or narrative reviews
2.	Published between 2011 and 2022	Out of the specified time range
4.	English language of publication	Language other than English
7.	In vivo (humans)	In vitro

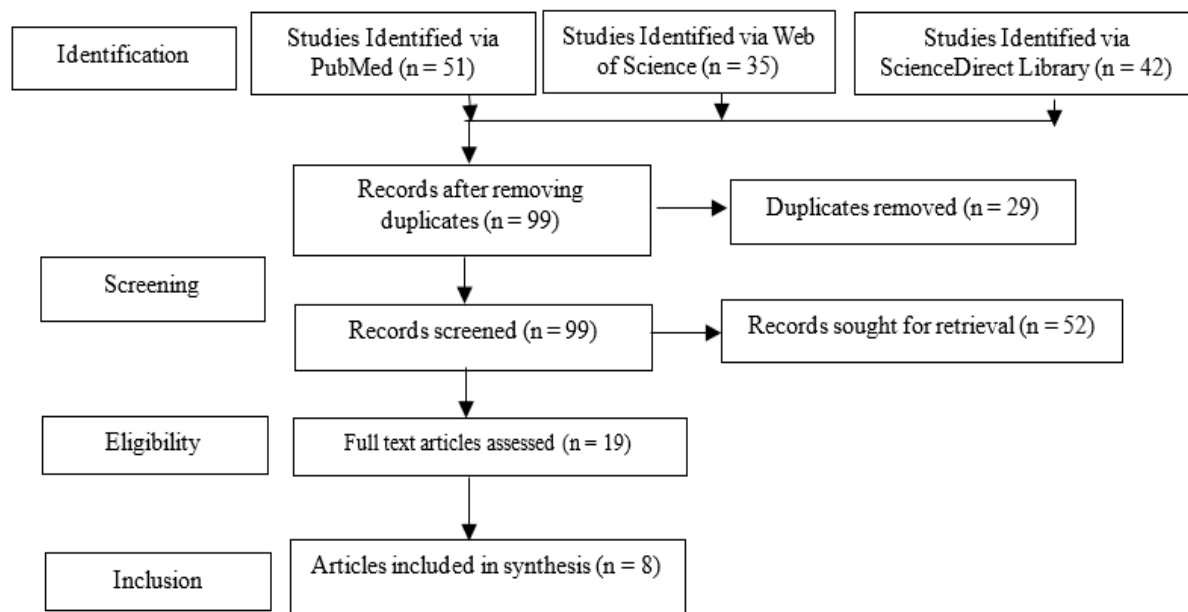


Figure 1. PRISMA Flow Diagram

Risk of Bias Assessment

Cochrane risk of bias assessment method was used to assess the studies' quality.

Table 2. Summary of Cochrane Risk of Bias Assessment

Study	Selection Bias/Appropriate control selection/baseline characteristics similarity	Selection bias in randomization	Selection bias in allocation concealment	Performance-related bias in blinding	Reporting bias/Selective reporting of outcomes	Detection bias Blinding outcome assessors	Accounting for confounding bias
Moreno et al., (2013) [14]	+	+	+	+	+	+	-
Alaff et al., (2014) [15]	+	+	+	+	-	+	-
Khullar et al., (2013) [16]	+	+	+	+	+	-	+
Kaya et al. (2013) [17]	+	+	+	+	+	+	-
Alkis et al. (2019) [18]	+	-	+	+	+	+	+
Almeshari et al. (2022) [19]	+	+	+	-	+	+	+
Gomes et al. (2015) [20]	+	+	+	+	+	+	+
Madfa et al. (2017) [21]	+	+	+	+	+	+	-

Results and Discussion

The results, objectives, number of participants, techniques, and statistical tests used in included studies are mentioned in Table 3.

Table 3. Summary of findings of selected studies

Authors name	Participants	Objective	Techniques	Statistical tests used	outcome
Moreno <i>et al.</i> (2013) [14]	688 adult	to assess the condition of the periradicular area and the quality of the crown restorations and root canal fillings.	In a dimly lit room, radiographs were processed on a computer screen, and the periradicular status was assessed using Strindberg's criteria.	Chi-squared test SPSS software	The periradicular condition of teeth with appropriate endodontic therapy and adequate restoration quality was found to be significantly better than the other combinations (P.01).
Alafif <i>et al.</i> (2014) [15]	200	The purpose of this study was to assess how the periapical health of a sample of adult Syrians was affected by poor coronal restoration and root canal filling.	Radiography	Chi-squared test	When the crown and the canal are adequately restored, periapical pathosis is not present in 96.6% of the instances.
Khullar <i>et al.</i> (2013) [16]	250	To ascertain the impact of root canal treatments and crown replacements on the periapical condition of endodontically treated teeth in a particular population.	Radiography	Chi-squared test	The periapical state of teeth with appropriate CR was much better (83.2%) than that of teeth with inadequate CR (37.2%).
Kaya <i>et al.</i> (2013) [17]	3850	To use digital panoramic radiographs to examine the oral health of an urban Turkish adult subpopulation with regard to the periapical status, the calibre of root fillings, and coronal restorations.	Radiography	Pearson's χ^2 test	Inadequate coronal restorations and root canal fillings were significantly correlated with the presence of AP ($p = 0.000$).
Alkis <i>et al.</i> (2019) [18]	245	To investigate the connection between periapical status, coronary restoration quality, and root canal treatment quality,	Radiography	Chisquare test	The connection between periapical status and a sufficient RCT was statistically significant ($P < 0.001$). There was a statistically significant correlation between appropriate RCT and periapical status, and there was a 40.5% frequency of apical periodontitis.
Almeshari <i>et al.</i> (2022) [19]	1000	In order to better understand the periapical status of endodontically treated teeth, Quality of Coronal Restoration and Root Canal Filling	Radiography	chi-squared and Fisher's exact tests	Because of the treatment's unfavourable prognosis, root canal fillings generally have poor technical quality.
Gomes <i>et al.</i> (2015) [20]	434	Analyze the Effects of Coronal Restoration and Endodontic Treatment on the Status of Periapical Tissues	Cone beam computed tomographic scans	chi-squared test	When the data were combined, it was discovered that the apical status of teeth with acceptable endodontic care and coronal restoration was much better than that of the other combinations ($P < .001$).
Madfa <i>et al.</i> (2017) [21]	200	to evaluate the quality of root canal fillings and coronal restorations in relation to the periapical state in a Yemeni population.	Radiography	chi-squared test	Apical periodontitis was present in 93.8% of natural teeth and 97.7% of teeth with inadequate intra-coronal restorations.

The cross-sectional research by Moreno *et al.* included data from 688 adults who presented for the first time at the Dental School of Santo Tomas University in Colombia. The periradicular state was assessed using the criteria of Strindberg while viewing radiographs on a computer screen in a dimly lit environment. Regarding endodontic therapy, just 33% of the teeth

were deemed successful. It was shown that peri-radicular conditions were strongly influenced by the quality of endodontic therapy and coronal restoration ($P = .001$). The results demonstrated that the peri-radicular status of teeth that had received both appropriate endodontic treatment and adequate restorations was considerably better than that of teeth that had received either treatment alone ($P = .01$) or treatment together ($P = .08$). When canals were filled up to 0–2 mm short of the apex as opposed to over- or under filled cases, there was a statistically significant rise in the proportion of teeth considered healthy ($P = .02$) [14].

Alafif *et al.* conducted research in which two hundred randomly chosen adult patients from Syria had their endodontically treated teeth radiated. The data were examined using the Chi-square test. Between teeth with suitable coronal restorations and those with adequate restorations, there was a considerable decrease in periapical pathosis ($P = 0.01$). Even though 14% of teeth were repaired with posts, the periapical tissues remained in good condition. Inadequate root canal fillings were much more common than appropriate ones, while only 18.5% of endodontic procedures were deemed adequate. When the crown and the canal are adequately restored, 96.6% of the time, periapical pathosis does not develop. In cases where only root canal fillings were adequate, the rate was 88.5%, and in cases where only coronal restorations were adequate, the rate was around 70%. A success percentage of 48.8 was found when treatment was subpar in both the coronal and root canal fillings [15].

Using cross-sectional radiography and orthopantomograms, the study by Khullar *et al.* evaluated the prevalence of apical periodontitis (AP) in teeth with root canal treatments in a particular population and the effect of coronal restorations (CR) and root canal fillings on periapical status (OPGs). 250 OPGs were analysed, and 438 of them had received root canal treatment (RCT). The Chi-square test outcomes, odds ratios, and p-values were recorded. The results showed that 53.1% of endodontically treated teeth had AP on radiographs. Comparing teeth with good RCT (32.3% prevalence) to teeth with unsatisfactory RCT (92.7%) reveals a substantial difference in the occurrence of AP. Additionally, there was a significant difference in the apical health of teeth between those with an adequate CR (83.2%) and those with an insufficient CR (37.2%). When both CR and root filling were adequate, the combined impact resulted in a substantially lower incidence of AP (21.6% vs. 97%) than when either parameter was insufficient [16].

Digital panoramic radiographs were employed by Kaya *et al.* to assess the oral health (periapical status, quality of root fillings, and coronal restorations) of an urban Turkish adult population [17]. Panoramic digital x-rays of the mouth were collected from patients ($n = 3,850$) who initially went to the Public Oral and Dental Health Center in Isparta, Turkey. The digital archive of the Isparta Public Oral and Dental Health Center was searched, and 1,000 digitised panoramic radiographs of a random sample of 28,000 teeth were found. In the data analysis, the Pearson's 2 test for independence was used, and a p-value less than 0.05 was considered significant. Out of the total of 28,000 teeth checked, 22,380 were found to be in good health (80.0%), whereas 4,732 were either missing (16.9%), filled (75.3%), or decaying (13.5%). There were only 601 root fillings (2.6% of all teeth), 247 of which were assessed to be of sufficient quality. 95 root-filled teeth, or 15% of the total, had AP (PAI 3–5). In root-filled teeth, the frequency of AP was 0.4%, but in normal teeth, it was 0.8%. Therefore, poor root canal treatments and coronal restorations were significantly associated with the development of AP ($p = 0.000$). The kind of tooth, the kind and quality of coronal restorations, the length and uniformity of root fillings, and the presence of cavities all had a significant impact on periapical health.

Alkis *et al.* scanned panoramic images from patients who sought treatment at the Oral and Maxillofacial Radiology Service at the Akdeniz University School of Dentistry in Turkey. A total of 245 adults participated in this cross-sectional research. Of 6064 teeth evaluated, 541 (8.9%) had RCT. The prevalence of apical periodontitis was determined to be 40.5%. A healthy rate of 62.3% was achieved in 334 cases of effective coronal restoration. For cases with pleasing coronal restorations, there was a substantial association between an acceptable RCT and periapical status ($P = 0.001$). A statistically significant correlation was found between appropriate RCT and periapical status, and apical periodontitis frequency was 40.5% [18].

In the research conducted by Almeshari from the dental school database at the University of Ha'il in Saudi Arabia, one thousand radiographs of teeth with endodontic treatment and permanent restorations were chosen randomly [19]. SPSS version 28 was used to do the statistical analysis of the data. The chi-squared and Fisher's exact tests examined the statistical significance of relationships between variables. A total of 1000 patients who had endodontic treatment were analyzed. There were 577 upper teeth (57.7%) and 423 lower teeth (42.3%). The majority of the samples ($n=487$, 48.7%) came from the posterior teeth (molars and premolars), whereas the front teeth ($n=205$, 20.5%) received the least attention. Apical periodontitis is prevalent in the Saudi population, the authors found. Subpopulation Root canal fillings are notorious for having a bad prognosis because of the low standard of technical excellence often applied to them. To improve the quality of endodontic care, substantial work is required.

Gomes *et al.* performed cone beam CT image analyses, and teeth were categorized as either healthy or otherwise based on their periapical condition. Out of the 434 people scanned, 1289 teeth were included in the analysis. Ultimately, 48.83% of the teeth that underwent treatment were deemed healthy. Only 55.11 percent of the teeth, however, were judged to have had adequate endodontic care. The presence or absence of an apical radiolucency was statistically related to the effectiveness of endodontic therapy and the presence of a coronal restoration ($P = 0.0001$). Compared to the other possible combinations, the apical state of teeth with successful endodontic treatment and coronal restoration was considerably significant. ($P = .001$). Compared to instances where the canal was overfilled or underfilled, the proportion of teeth classified as healthy was considerably greater in those where the canal was filled to within 0-2 mm of the apex ($P = .001$). Statistical analysis showed that having a position there wasn't a significant influence ($P = .81$) [20].

Madfa *et al.* conducted research at Al Hamzi Dental Center in Sana'a, Yemen, including two hundred digitized panoramic radiographs. To analyze the statistical significance between variables, the Chi-square test was performed. Apical periodontitis was identified in 93.6% of root-filled teeth. Root-filled teeth had a satisfactory root canal filling quality in only 9.2% of cases, and periapical disease was present in 32.3% of cases. Roots with defective root canal fillings were characterized by a prevalence of periapical illness of 95.4%. Apical periodontitis was present in 93.8% of natural teeth and 97.7% of teeth with inadequate intra-coronal restorations. Of the root-filled teeth, 52.7% had crown restorations, with 91.0% having periapical lesions [21].

The peri-radicular conditions of teeth in this research were considerably better when coronal restorations were of appropriate quality than those of teeth with deficient or missing restorations. Teeth with appropriate endodontic treatment and coronal restoration fared the best, with a considerably higher healthy rate than the other studies. Post-treatment apical periodontitis is most often caused by intraarticular infection, which has a higher risk of persisting or developing in teeth that have been improperly treated. Note that radiographic evaluation of filling quality served as a proxy for treatment efficacy. While the state of teeth classified as effectively treated was much better than that of badly treated teeth, the frequency of apical periodontitis was nevertheless unexpectedly high (39%). This equates to a 61% success rate, much lower than the 90%-95% success rates often associated with scholarly research. Many of the teeth classified as effectively treated were likely not so, which would explain the disparity. This is because teeth were graded based on the filling quality, without information on the disinfection procedures, and because radiographs have well-known limits to judging the quality of endodontic treatment [22].

Some research has linked the use of canal posts to an increased risk of periapical pathosis, perhaps due to leaking during post-space preparation, a lack of regular irrigation, or the deterioration of any residual gutta-percha [23]. The research concluded that there is no correlation between the post and the result of the therapy. Similar findings were found in other research efforts. Only 18.5 percent of root canals were appropriately filled, which is relatively low compared to previous research showing root canal therapy as a reliable therapeutic option [24]. This study found a strong association between periapical pathosis and subpar root canal therapy; further research corroborated similar findings [25].

It has also been argued that the constraints of the radiographic evaluation as a research technique mean that periapical diagnosis using OPGs may underestimate the true incidence of AP. Using a two-dimensional picture to judge the quality of a three-dimensional structure is one such constraint, and it affects both the root canal filling and the CR. Nevertheless, using radiographic imaging to diagnose periapical infection or coronal leaking has been common practice. Previous research by Asgary *et al.* examined what elements would still be at play 8 to 10 years following root canal therapy, indicating how effective the procedure was. Successful apical healing occurred in 86% of instances with pulp necrosis and periapical radiolucency [26]. The success rate was higher than 96% for individuals with live or nonvital pulps but no periapical radiolucency.

Similar to earlier publications [27], mandibular first molars were the most often missing teeth in the current investigation. The prevalence of AP in the mandibular molars was most significant in this sampled cohort. Mandibular molars were also the most common site of RFT. The molars are the first teeth to emerge and are also the most vulnerable and often treated teeth. The root canal anatomy of these teeth is the most complicated. Other studies [28] have shown that AP is more common in molars than in front teeth.

The rate of RCT ranges from 1.3% to 20%, according to previous research evaluating the frequency of endodontic therapy [29]. This research indicated that 8.9% of the Turkish subpopulation is affected by this condition (Antalya). Although a link between periapical health and coronal restoration quality was discovered by Gencoglu *et al.*, the authors decided that RCT quality was more beneficial. Furthermore, both Gencoglu *et al.* [30] and Kalender *et al.* [31] reported that adequately powered RCTs demonstrated a favorable outcome independent of the quality of coronal restoration.

The current research found a greater frequency of apical periodontitis than in earlier studies, at 27.4%. The significant prevalence of apical periodontitis in our research may be explained by the high frequency of substandard root canal therapy and coronal restorations. This assertion has been validated by previous research examining how endodontic therapy quality affected peri-radicular tissues. In line with the findings of Kamberi *et al.* [32], this study demonstrated no statistically significant difference in the prevalence of apical periodontitis between maxillary (27%) and mandibular (27.9%) teeth. Based on tooth position, the prevalence of apical periodontitis was higher in anterior root-filled teeth (34.6% vs. 25.5%). This finding ran counter to those of comparative research done in the past. The anatomical complexity of the back teeth is defended by Craveiro *et al.* "Curvatures, an additional canal that might be overlooked." "The canal splits in the medial or apical third, stones and calcification" are all anomalies in the front teeth that could make root canal therapy more difficult [33].

Although the prevalence of apical radiolucency in treated teeth in the current study (51.1%) is higher than the success rates of endodontic therapy, it is still within the range reported by several earlier cross-sectional studies that used peri-apical or panoramic radiographs for the assessment. Consistent with other research, our findings that inadequate endodontic treatment was associated with a high incidence of apical radiolucency support the validity of this hypothesis. The primary cause of post-treatment discomfort is an infection in the intraarticular space, which may arise or persist if certain endodontic therapy stages fail. Apart from the presence of the coronal restoration, inadequate root canal filling had a significantly higher prevalence of apical radiolucency than adequately treated canals, indicating that the quality of endodontic treatment is the most important factor in determining the condition of the apical tissues in our study. Several other studies have shown

similar findings, highlighting the need to focus on appropriate training for endodontic therapy [34].

Conclusion

The effectiveness of root canal therapy and coronal restoration and the frequency of periapical issues are significantly correlated. To sustain a healthy periodontium, focus should therefore be placed on enhancing and maintaining the standard of root canal therapy and restorations.

Acknowledgments: We would like to acknowledge the help of Riyadh Elm University research center.

Conflict of interest: None

Financial support: None

Ethics statement: This study fulfils the ethical requirements of Riyadh Elm University.

References

1. Asgari I, Soltani S, Sadeghi SM. Effects of iron products on decay, tooth microhardness, and dental discoloration: a systematic review. *Arch Pharm Pract.* 2020;11(1):60-82.
2. Ismail F, Muneer MU, Ahmed AR, Hussain MW, Farhan M, Khan MU, et al. Factors affecting cognition in individuals with tooth loss. *Ann Dent Spec.* 2019;7(4):7-13.
3. Hamed MT, Mously HA. Investigating economic and clinical implications of tooth implant supported prosthesis among patients and practitioners. *Int J Pharm Res Allied Sci.* 2019;8(4):116-21.
4. Torabinejad M, Walton RE, Fouad A, SCOTT J. *Endodontie: principes et pratique.* Elsevier Health Sciences; 2016.
5. Zahran M, El-Madhoun M, Redwan S, Merdad K, Sonbul H, Sabbahi D. Treatment concepts for restorations of endodontically treated teeth: Survey of dentists in Jeddah city, Saudi Arabia. *Saudi Endod J.* 2021;11(2):154.
6. Holland R, Gomes JE Filho, Cintra LTA, Queiroz ÍOA, Estrela C. Factors affecting the periapical healing process of endodontically treated teeth. *J Appl Oral Sci.* 2017;25(5):465-76.
7. Gillen BM, Looney SW, Gu LS, Loushine BA, Weller RN, Loushine RJ, et al. Impact of the quality of coronal restoration versus the quality of root canal fillings on success of root canal treatment: a systematic review and meta-analysis. *J Endod.* 2011;37(7):895-902.
8. Al Hablain E. Periapical Tissue Status of Endodontically Treated Teeth Restored with Fixed Coronal Restoration: A Cone-beam Computed Tomographic Study. *EC Dent Sci.* 2022;21:32-41.
9. Hargreaves KM. *Cohen's pathways of the pulp.* Elsevier; 2016.
10. Ng YL, Mann V, Rahbaran S, Lewsey J, Gulabivala K. Outcome of primary root canal treatment: systematic review of the literature—Part 2. Influence of clinical factors. *Int Endod J.* 2008;41(1):6-31.
11. Pak JG, Fayazi S, White SN. Prevalence of periapical radiolucency and root canal treatment: a systematic review of cross-sectional studies. *J Endod.* 2012;38(9):1170-6.
12. Al-Omari MA, Hazaa A, Haddad F. Frequency and distribution of root-filled teeth and apical periodontitis in a Jordanian subpopulation. *Oral Surg Oral Med Oral Pathol Oral Radiol Endod.* 2011;111(1):e59-65.
13. Kielbassa AM, Frank W, Madaus T. Radiologic assessment of quality of root canal fillings and periapical status in an Austrian subpopulation—An observational study. *PloS one.* 2017;12(5):e0176724.
14. Moreno JO, Alves FR, Gonçalves LS, Martinez AM, Rôças IN, Siqueira Jr JF. Periradicular status and quality of root canal fillings and coronal restorations in an urban Colombian population. *J Endod.* 2013;39(5):600-4.
15. Alafif H. Impact of the quality of coronal restoration and root canal filling on the periapical health in adult Syrian subpopulation. *Indian J Dent.* 2014;5(2):8-13.
16. Khullar P, Raisingani D, Gupta S, Khatri RK. A survey report on effect of root canal fillings and coronal restorations on the periapical status of endodontically treated teeth in a selected group of population. *Int J Clin Pediatr Dent.* 2013;6(2):89.
17. Kaya BU, Kececi AD, Guldaz HE, Orhan H. A retrospective radiographic study of coronal-periapical status and root canal filling quality in a selected adult Turkish population. *Med Princ Pract.* 2013;22(4):334-9.
18. Alkis HT, Kustarci A. Radiographic assessment of the relationship between root canal treatment quality, coronal restoration quality, and periapical status. *Niger J Clin Pract.* 2019;22(8):1126.
19. Almeshari SA, Alrakkad RA, Alshammari GD, Alshammari RH, Madfa AA. Periapical Status of Endodontically Treated Teeth in Relation to the Quality of Root Canal Filling and Coronal Restoration: A Radiographic Study. *Divers Equal Health Care.* 2022;19:19.
20. Gomes AC, Nejaim Y, Silva AI, Haiter-Neto F, Cohenca N, Zaia AA, et al. Influence of endodontic treatment and coronal restoration on status of periapical tissues: a cone-beam computed tomographic study. *J Endod.* 2015;41(10):1614-8.

21. Madfa A, Al-Hamzi M, Senan E. Cross-sectional assessment of the periapical status as related to the quality of root canal fillings and coronal restorations in a Yemeni population. *J Oral Res.* 2017;6(1):19-24.
22. Siqueira JF Jr, Rôças IN. Clinical implications and microbiology of bacterial persistence after treatment procedures. *J Endod.* 2008;34(11):1291-301.
23. Tavares PB, Bonte E, Boukpepsi T, Siqueira JF Jr, Lasfargues JJ. Prevalence of apical periodontitis in root canal-treated teeth from an urban French population: influence of the quality of root canal fillings and coronal restorations. *J Endod.* 2009;35(6):810-3.
24. Kayahan MB, Malkondu O, Canpolat C, Kaptan F, Bayirli G, Kazazoglu E. Periapical health related to the type of coronal restorations and quality of root canal fillings in a Turkish subpopulation. *Oral Surg Oral Med Oral Pathol Oral Radiol Endod.* 2008;105(1):e58-62.
25. Wu MK, Shemesh H, Wesselink PR. Limitations of previously published systematic reviews evaluating the outcome of endodontic treatment. *Int Endod J.* 2009;42(8):656-66.
26. Asgary S, Shadman B, Ghalamkarpour Z, Shahravan A, Ghoddsi J, Bagherpour A, et al. Periapical status and quality of root fillings and coronal restorations in Iranian population. *Int Endod J.* 2010;5(2):74-82.
27. Shigli K, Hebbal M, Angadi GS. Relative contribution of caries and periodontal disease in adult tooth loss among patients reporting to the Institute of Dental Sciences, Belgaum, India. *Gerodontology.* 2009;26(3):214-8.
28. Chrysanthakopoulos NA. Reasons for extraction of permanent teeth in Greece: a five-year follow-up study. *Int Dent J.* 2011;61(1):19-24.
29. Gencoglu N, Pekiner FN, Gumru B, Helvacioğlu D. Periapical status and quality of root fillings and coronal restorations in an adult Turkish subpopulation. *Eur J Dent.* 2010;4(1):17-22.
30. Kalender A, Orhan K, Aksoy U, Basmaci F, Er F, Alankus A. Influence of the quality of endodontic treatment and coronal restorations on the prevalence of apical periodontitis in a Turkish Cypriot population. *Med Princ Pract.* 2013;22(2):173-7.
31. Kamberi B, Hoxha V, Stavileci M, Dragusha E, Kuçi A, Kçiku L. Prevalence of apical periodontitis and endodontic treatment in a Kosovar adult population. *BMC Oral Health.* 2011;11(1):1-6.
32. Craveiro MA, Fontana CE, de Martin AS, da Silveira Bueno CE. Influence of coronal restoration and root canal filling quality on periapical status: clinical and radiographic evaluation. *J Endod.* 2015;41(6):836-40.
33. Georgopoulou MK, Spanaki-Voreadi AP, Pantazis N, Kontakiotis EG, Morfis AS. Periapical status and quality of root canal fillings and coronal restorations in a Greek population. *Quintessence Int.* 2008;39(2):e85-92.
34. Patel S, Dawood A, Whaites E, Pitt Ford T. New dimensions in endodontic imaging: part 1. Conventional and alternative radiographic systems. *Int Endod J.* 2009;42(6):447-62.