

MESENTERIC ISCHEMIA: REVIEW OVER PATHOPHYSIOLOGY AND MEANS OF TREATMENTS IN SURGICAL DEPARTMENT

Hussam Adnan Abualhamayel^{1*}, Mohammed Yahya Alsayed², Fuad Mohammed Alkudaysi², Abdulrahman Awadh Almarhabi², Omar Ahmed Ghanem³, Meshari Talal Alanazi⁴, Abdullah Omar Alsaeri⁵, Bader Ahmad Alshammari⁶, Fahad Sanad Binkattal⁷, Nasser Tareq Aldosari⁸, Walaa Jamal Hommadi⁹

1. Faculty of Medicine, King Abdulaziz University, Jeddah, KSA.
2. Faculty of Medicine, Umm Al Qura University, Makkah, KSA.
3. Faculty of Medicine, Taibah University, Madinah, KSA.
4. Faculty of Medicine, Dar Al Uloom University, Riyadh, KSA.
5. Faculty of Medicine, Bisha University, Bisha, KSA.
6. MBBS, Al Jahra Hospital, Al Jahra, Kuwait.
7. MBBS, Al Adan Hospital, Hadiya, Kuwait.
8. MBBS, Al Amri Hospital, Kuwait, Kuwait.
9. Faculty of Medicine, Batterjy Medical College, Jeddah, KSA.

ARTICLE INFO

Received:

10 Jun 2021

Received in revised form:

03 Oct 2021

Accepted:

12 Oct 2021

Available online:

28 Oct 2021

Keywords: Acute mesenteric ischemia, Chronic mesenteric ischemia, Nonocclusive mesenteric ischemia, Mesenteric venous thrombosis, Endovascular repair, Open repair

ABSTRACT

Mesenteric ischemia is rare, yet a fatal etiology of abdominal pain. It is common in the elderly population, specifically women more than men. Mesenteric ischemia manifests itself in a variety of presentations and has a range of causes, and always poses a diagnostic challenge. A high index of suspicion is needed, and early identification and intervention raise the survival rate of the patients. Because of its high accuracy performance, computed tomographic angiography (CTA) has become the gold standard diagnostic modality. Options for intervention include endovascular procedures and open repair. We aimed to review the literature to promote the understanding and awareness of mesenteric ischemia. We reviewed the literature for mesenteric ischemic syndromes, pathophysiology, diagnosis, evaluation, and treatment options. Articles were chosen from the PubMed database, and selected studies were subjected to a thorough review. Mesenteric ischemia is a rare cause of abdominal pain, yet it is a potentially life-threatening condition. To diagnose and treat the condition early, a high index of suspicion is essential. Delay in diagnosis and treatment might result in a high rate of morbidity and mortality for the patient. Early bowel revascularization with an open or endovascular repair is critical for survival.

This is an open-access article distributed under the terms of the [Creative Commons Attribution-Non Commercial-Share Alike 4.0 License](https://creativecommons.org/licenses/by-nc-sa/4.0/), which allows others to remix, tweak, and build upon the work non commercially, as long as the author is credited and the new creations are licensed under the identical terms.

To Cite This Article: Abualhamayel HA, Alsayed MY, Alkudaysi FM, Almarhabi AA, Ghanem OA, Alanazi MT, et al. Mesenteric Ischemia: Review Over Pathophysiology and Means of Treatments in Surgical Department. *Pharmacophore*. 2021;12(5):25-31. <https://doi.org/10.51847/OhHRXDSzdx>

Introduction

Mesenteric ischemia is a life-threatening etiology of abdominal pain. It is caused by a compromised blood flow that does not align with the metabolic requirements of visceral organs. The gravity of this condition differs by the type of vessel, and ultimately the organ, involved and the status of the collateral blood flow [1]. Although there are advances in the diagnostic measurements used to identify this condition, the most crucial factor that manipulates the outcome of this condition has always been the prompt diagnosis and intervention. Delayed or inaccurate detection may result in tragic complications that raise the mortality up to 80% among acute presentations [2, 3]. Even though it is considered a rare etiology of abdominal pain, it is one of the most serious causes accounting for 0.09–0.2% of all acute surgical admissions [4]. In this review, we shed the light on

Corresponding Author: Hussam Adnan Abualhamayel; Faculty of Medicine, King Abdulaziz University, Jeddah, KSA. E-mail: ihosam.a97@gmail.com.

the pathophysiology, presentation, diagnosis, and treatment measures of the various syndromes of this condition. The aim is to promote understanding and awareness of this fatal condition.

Materials and Methods

We utilized the PubMed database for the selection process of relevant articles, and the following keys used in the mesh ((“Mesenteric Ischemia”[Mesh]) OR (“Pathophysiology”[Mesh] OR “Diagnosis”[Mesh] OR “Evaluation”[Mesh] OR “Treatment”[Mesh])). For the inclusion criteria, the articles were selected based on including one of the following: Mesenteric ischemia or Mesenteric ischemia’s pathophysiology, diagnosis, evaluation, and treatment. Exclusion criteria were all other articles that did not meet the criteria by not having any of the inclusion criteria results in their topic.

Review

Types of Mesenteric Ischemia

Mesenteric ischemia can broadly be classified as either arterial or venous, see **Figure 1**. Arterial obstruction is the most common etiology of mesenteric ischemia and has both acute and chronic types. The arterial disease can be further subdivided into occlusive and nonocclusive mesenteric arterial ischemia. The occlusive type is mostly associated with embolic in 40-50% of cases, with thrombotic occlusion accounting for 20 to 35% of cases, and with dissection or vasculitis accounting for 5% of cases [1]. Nonocclusive mesenteric ischemia is thought to be caused by a hypoperfusion state associated with mesenteric vasoconstriction. It constitutes 5 to 15% of all mesenteric ischemia cases, and the incidence is subsiding owing to the promoted awareness of this condition and the improvement of supportive therapies [5, 6]. The last type is mesenteric venous thrombosis, which accounts for 5-15% of mesenteric ischemia cases. It causes impairment in the venous flow that leads to visceral edema and abdominal pain. It is thought to be caused idiopathically, however, the majority of the cases have predisposing conditions. These include trauma, hypercoagulable states, pancreatitis, or tumors [7, 8].

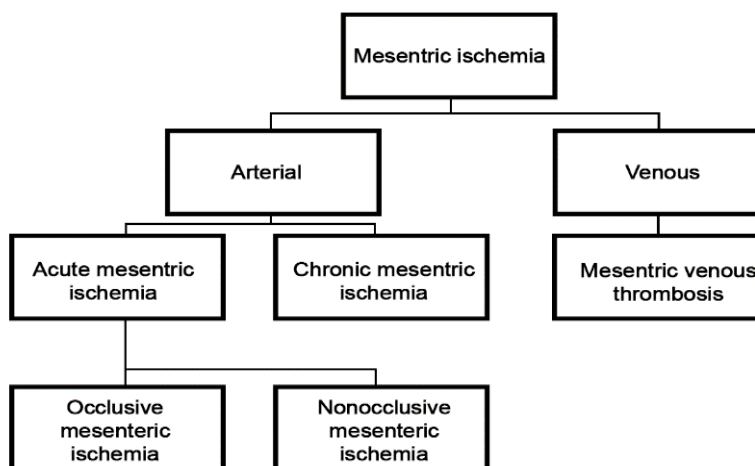


Figure 1. Types of Mesenteric Ischemia

Pathophysiology

The mesenteric circulation consists of three major arteries; celiac artery, superior mesenteric artery, and inferior mesenteric artery. These three major arteries are connected with collateral networks that play a part in the event of a single artery breakdown, to compensate for the insufficiency in the perfusion of viscera [9]. In the setting of an acute condition, the loss of blood flow in the major artery (most commonly the superior mesenteric artery) and its collateral vessels lead to mesenteric ischemia [10, 11]. On the contrary, in chronic mesenteric ischemia, collateral vessels develop over time, and symptoms may not appear unless two or more major vessels are occluded [12].

When ischemia takes place due to decreased blood flow, the body initially responds by vasodilation in an attempt to increase the blood and oxygen delivery to the visceral organs [13, 14]. As time passes, the protracted ischemia results in vasoconstriction which primarily inflicts injury to the intestinal mucosa. Consequently, bacterial translocation ensues due to the failure of the mechanisms that prevent otherwise. Moreover, systemic inflammatory response joins in the process, leading to further vasospasm and ischemia, and more ferocious damage to the bowel wall. If untreated, this can lead to irreversible transmural intestinal necrosis, and ultimately death [13, 15].

Clinical Assessment

Attention must be drawn to the patient’s history and clinical examination findings hinting out towards mesenteric ischemia to make a definitive diagnosis and prompt treatment. In terms of incidence, mesenteric ischemia more commonly affects women than men [16]. The treating physician should be attentive during clinical assessment for any evidence of vascular and

atherosclerotic diseases, such as a peripheral artery, cerebrovascular, coronary artery, renovascular disease. Moreover, pulmonary and cardiovascular disease need to be treated as they occur along with mesenteric ischemia, and may hinder the options of revascularization [1].

Presentation of Acute and Chronic Mesenteric Ischemia

Patients suffering from acute mesenteric ischemia often, but not always, present with abdominal pain that is out of proportion to clinical examination along with bruit in the epigastrium. Some patients may only complain of tenderness upon palpation due to peritoneal irritation from injured bowel. Interestingly, this finding may shift the physician's attention to other diagnoses, rather than acute mesenteric ischemia [17, 18]. If the patient presents with acute onset abdominal pain, they should always look for the possibility of atherosclerotic process and source of emboli, such as the history of myocardial infarction and atrial fibrillation [4, 11]. It is not easy to ascertain arterial from venous occlusion; nonetheless, patients with venous occlusion often present with a gradual onset abdominal pain. Furthermore, risk factors for venous disease such as deep vein thrombosis, recent abdominal surgery, thrombophilia, and cancer can give a clue toward venous occlusion [7, 19].

For chronic mesenteric ischemia patients, they present with various symptoms, such as nausea and vomiting, abdominal pain, postprandial pain, altered bowel movement, and weight loss [12, 16]. Postprandial pain needs a detailed inquiry, because it occurs in many other diseases, including gastric reflux, peptic ulcer disease, biliary disease, pancreatitis, irritable bowel syndrome, and gastroparesis. For that reason, a full gastroenterology workup is needed to rule out these differentials [20]. Another finding that may distinct chronic mesenteric ischemia from these diseases is weight loss, as it is common in mesenteric ischemia. Cancer is common in individuals of old age with a history of smoking, as well as the case for chronic mesenteric ischemia. Therefore, attention towards the possibility of cancer should not delay the recognition of chronic mesenteric ischemia. Essentially, in elderly women complaining from loss of weight, dietary changes, and have a history of vascular disease, chronic mesenteric ischemia must be taken into consideration [16, 20].

Laboratory Tests

The most important laboratory tests to check in possible cases of acute mesenteric ischemia are fluid status, basic metabolic panel (BMP), arterial blood gases (ABG), and markers for infection [21]. In the event of bowel ischemia or bowel infarction, lactate levels can be rising. However, it is not beneficial to wait for the lactate to rise to move on to further testing. Early intervention before lactic acidosis ensues helps salvage more bowel from transmural damage [22]. Physician should also look for evidence of infection, including a left shift of neutrophils or an increased white blood cell count. These findings point out ischemia, full-thickness bowel damage, or translocation of bacteria [21].

Up to this point, there are no serum biomarkers that proved worthy to early detect acute mesenteric ischemia [23, 24]. This is due to the early metabolism of the liver for any proteins secreted by the intestinal cells [13]. C-reactive protein, albumin, transferrin, and transthyretin are the only useful markers in cases of chronic mesenteric ischemia because they are valuable in evaluating the level of malnutrition before undergoing revascularization [16].

Diagnostic Imaging

Ultrasonography

Duplex ultrasonography is an effective study in diagnosing mesenteric vasculature, and it has high sensitivity and specificity reaching 85 to 90%. It is advantageous in being a low-cost study that can a fair assessment of the proximal visceral vessels, however it is limited sometimes distally [25, 26]. The factors that may decrease the effectiveness of this study include operator dependency, obesity, bowel gas, vessels calcification. Normally, this study is adequate for evaluating patients with chronic mesenteric ischemia and for follow-up after an intervention [27].

Computed Tomographic and Magnetic Resonance Angiography

Computed tomographic angiography (CTA) has become the gold standard imaging modality for diagnosing mesenteric ischemic syndromes since it has a high accuracy of 95 to 100% [28]. It is reliable in obtaining rapid images of the origin and length of the vasculature. Moreover, it provides a good characterization of the degree of stenosis or obstruction and assesses the branch vessels. It also helps in evaluating the options for revascularization [17, 29]. Additionally, CTA can detect the potential origin of the emboli, and assess other abdominal structures and pathologies. To determine the presence of acute mesenteric ischemia, CTA needs to be performed with intravenous contrast enhancement. Compared to arterial disease, CTA does not have a high sensitivity for mesenteric venous thrombosis. However, it gets better with the use of two-phase imaging [8, 30].

Magnetic resonance angiography (MRA) is a choice to use to avoid the risks of radiation and contrast material. Nevertheless, due to long operation time, low image resolution, and overestimation of the grade of stenosis, CTA is almost always the preferred option [17]. The pros of CTA greatly outbalance the disadvantages in patients suffering from acute mesenteric ischemia [31].

Endoscopy

Endoscopy is one of the modalities used for evaluating abdominal pain. It is most helpful in detecting other differential diagnoses. These include ischemic abnormalities in the stomach, proximal small intestines, large colon, and rectum. The

drawback of this modality is that it cannot reach the parts of the small intestines most commonly affected by mesenteric ischemia. Moreover, it is only capable of detecting late abnormalities, such as infarction. Thus, it is not accurate in identifying subtle ischemic abnormalities [32].

Catheter Angiography

Catheter angiography has evolved from previously being a standard modality of diagnosing mesenteric ischemia, to being a part of the initial interventional treatment. It is carried out after the option of revascularization is decided. To regain the flow of blood, it is complemented with endovascular therapies, including angioplasty, stenting, thrombolysis, and arterial vasodilation [33-35]. Furthermore, catheter angiography aids in confirming the diagnosis before commencing open abdominal exploration [17].

Immediate Care and Treatment

Fluid and Electrolyte Replacement

Fluid replacement, monitoring of electrolyte levels, and continuous hemodynamic monitoring are crucial steps in initial care. This is due to severe metabolic acidosis and hyperkalemia that can arise in acute mesenteric ischemia patients resulting from bowel infarction [13, 17]. Furthermore, from this point the patient's condition may deteriorate to sepsis or septic shock. Principally, fluid replacement should be cautiously adjusted to avert fluid overload, because the fluid demand may be very high, particularly following revascularization. The requirement can reach up to 2 liters of crystalloid fluid during the first 24 hours subsequent to revascularization [1].

Early Pharmacological Treatment

Heparin needs to be given early in the course in patients suffering from acute mesenteric ischemia or aggravation of chronic mesenteric ischemia. Moreover, vasodilators can be given for unresolving vasospasm following revascularization [14]. Broad-spectrum antibiotics have shown to improve the outcomes of critically ill individuals and those with high risk of infection [36, 37]. This is true due to the increased hazard of bacterial translocation and sepsis [38, 39].

Lines of Treatment

Acute Mesenteric Ischemia

Endovascular Repair

The use of endovascular repair is getting more common. One study showed that the use of this approach has increased from 15% to 30% from year 2005 to 2009. This is owing to the fact that it can restore blood flow more abruptly than open approach, and therefore halts the progression of ischemia toward bowel infarction [40]. Even though the use of this approach is getting more prevalent, there are not enough data that shows an obvious advantage of this technique over open repair. In fact, endovascular repair is most effective in cases of ischemia that is not serious, and in those with serious comorbidities that put them at high risk of adverse effects of open repair [3, 41, 42].

Endovascular repair treats acute obstruction by mechanical thrombectomy or angioplasty accompanied with stenting. For more effectiveness, these techniques are complemented with thrombolysis to remove any remaining thrombi [41]. Moreover, endovascular procedures are functional in managing both thrombotic and embolic obstructions [34, 43]. Endovascular repair has a drawback in which it cannot directly evaluate bowel viability. Therefore, patients undergoing this approach must be closely monitored for any evidence of peritonitis, as it entails emergent open exploration for bowel resection [34, 42].

Open Repair

The aims of open repair approach are to relieve the obstruction in the occluded vessel, evaluate bowel viability, and to resect dead bowel sections. Acute obstruction by emboli is treated by embolectomy. If failed, bypass with an autologous graft can be done distal to the obstruction. Nevertheless, if distal flow is still defective, thrombolytic drugs can be administered intraarterially [44]. Following these steps, the viability of the bowel and other organs is assessed for ischemia. Complete ischemic bowel sections are resected, while sections that seem suspicious can be left for future reassessment or operation [3, 42, 45]. Short-term mortality following open repair spans between 26 to 65%, and it gets higher in patient with comorbidities, such as old age, renal failure, metabolic acidosis, and longer duration of symptoms [3, 45, 46].

Chronic Mesenteric Ischemia

The option of intervention for chronic mesenteric ischemia is decided by weighing the benefits and risks. Endovascular repair has exceeded open repair in recent years. This is due to the immediate relief of symptoms it provides, less risk of adverse effects, and for being less invasive [47]. Nonetheless, it is associated with higher rates of failure of patency, and the time it takes for symptoms to reappear is shorter [48, 49]. Restenosis affects up to 40% of patients, and 20 to 50% of those who experience it will require reintervention [50, 51]. On the other hand, open approach is associated with slower recovery time and longer duration of hospital stay than endovascular approach. Although data on mortality is inconclusive, patients treated with open repair have higher rates of symptom alleviation and primary patency after 5 years, as well as reduced rates of reintervention [52]. For younger, lower-risk individuals with a longer life expectancy, or for those whose lesions are not receptive to endovascular procedures, open repair may be a better option [53].

Nonocclusive Mesenteric Ischemia

The mortality in patients with nonocclusive mesenteric ischemia can reach up to 83%, depending on how well the underlying etiology is managed. The primary goal of management is to treat hemodynamic instability, and to reduce the usage of systemic vasoconstrictors [2]. In patients without bowel infarction, further therapeutic options include anticoagulation and the use of vasodilators. Serial abdominal examinations should be used to keep track of patients. Moreover, If the likelihood of peritonitis is a concern, open exploration must be done [15].

Mesenteric Venous Thrombosis

Except if contraindicated, all individuals with venous mesenteric ischemia need to be treated with intravenous heparin, which should be switched to long-term oral coagulation 24 to 48 hours after the acute state has stabilized. Anticoagulation is usually the sole treatment required; patients who take anticoagulation have reduced rates of treatment failure and death than those who do not [19, 54]. In patients who have failed to respond to medical treatment, there are a variety of options for intervention, including percutaneous and transhepatic thrombectomy, local thrombolysis, and open intraarterial thrombolysis [55]. Any signs of peritonitis, or gastrointestinal bleeding, as in all cases of mesenteric ischemia, should prompt open exploration to rule out bowel infarction [42].

Follow-Up

Patients with mesenteric ischemia should follow long-term therapy plan that aims on treating concomitant conditions and risk factors. Thus, smoking abstinence, blood pressure control, and statin medication are all suggested. All patients who have undergone endovascular or open procedure should take life-long aspirin as a preventive therapy. Furthermore, they need to take clopidogrel for a period of 1 to 3 months following the intervention [56]. Lifelong anticoagulant therapy is advised for patients with venous mesenteric ischemia, atrial fibrillation, familial or sporadic thrombophilia [19]. It is recommended that vascular patency be assessed lifelong on a regular basis, as the recurrence of symptoms is quite common. For the first year after repair, duplex ultrasonography should be done every six months, then once a year after that [57]. Any symptom recurrence should necessitate diagnostic imaging and reintervention, if signs of restenosis or obstruction are discovered [34, 42].

Conclusion

Mesenteric ischemia is an uncommon etiology of acute abdomen; however, it is a potentially serious surgical emergency. A high index of clinical suspicion is required in order to early diagnose and treat the condition. Delayed diagnosis and intervention may pose the patient to a high morbidity and mortality. The key to a patient's survival is early bowel revascularization with open or endovascular repair. Moreover, it is critical to provide rigorous postoperative care to avoid multi-organ failure, and to recognize complications of mesenteric revascularization as soon as possible.

Acknowledgments: The authors are grateful to all support and guidance of Dr. Hussam Adnan Abualhamayel.

Conflict of interest: None

Financial support: None

Ethics statement: None

References

1. Oldenburg WA, Lau LL, Rodenberg TJ, Edmonds HJ, Burger CD. Acute mesenteric ischemia: a clinical review. *Arch Intern Med.* 2004;164(10):1054-62. doi:10.1001/ARCHINTE.164.10.1054
2. Schoots IG, Koffeman GI, Legemate DA, Levi M, Van Gulik TM. Systematic review of survival after acute mesenteric ischaemia according to disease aetiology. *Br J Surg.* 2004;91(1):17-27. doi:10.1002/BJS.4459
3. Park WM, Głowiczki P, Cherry Jr KJ, Hallett Jr JW, Bower TC, Panneton JM, et al. Contemporary management of acute mesenteric ischemia: Factors associated with survival. *J Vasc Surg.* 2002;35(3):445-52. doi:10.1067/MVA.2002.120373
4. Bala M, Kashuk J, Moore EE, Kluger Y, Biffl W, Gomes CA, et al. Acute mesenteric ischemia: guidelines of the World Society of Emergency Surgery. *World J Emerg Surg.* 2017;12(1):1-11. doi:10.1186/S13017-017-0150-5
5. Acosta S. Epidemiology of mesenteric vascular disease: clinical implications. *Semin Vasc Surg.* 2010;23(1):4-8. doi:10.1053/J.SEMVASCSURG.2009.12.001
6. Howard TJ, Plaskon LA, Wiebke EA, Wilcox MG, Madura JA. Nonocclusive mesenteric ischemia remains a diagnostic dilemma. *Am J Surg.* 1996;171(4):405-8. doi:10.1016/S0002-9610(97)89619-5
7. Kumar S, Sarr MG, Kamath PS. Mesenteric venous thrombosis. *N Engl J Med.* 2001;345(23):1683-8. doi:10.1056/NEJMRA010076
8. Morasch MD, Ebaugh JL, Chiou AC, Matsumura JS, Pearce WH, Yao JS. Mesenteric venous thrombosis: A changing clinical entity. *J Vasc Surg.* 2001;34(4):680-4. doi:10.1067/MVA.2001.116965

9. Rosenblum JD, Boyle CM, Schwartz LB. The mesenteric circulation. *Anatomy and physiology. Surg Clin North Am.* 1997;77(2):289-306. doi:10.1016/S0039-6109(05)70549-1
10. Kerzmann A, Haumann A, Boesmans E, Detry O, Defraigne JO. Acute mesenteric ischemia. *Rev Med Liege.* 2018;73(5-6):300-3. Available from: <https://pubmed.ncbi.nlm.nih.gov/29926570/>
11. Acosta S. Mesenteric ischemia. *Curr Opin Crit Care.* 2015;21(2):171-8. doi:10.1097/MCC.000000000000189
12. Patel R, Waheed A, Costanza M. Chronic Mesenteric Ischemia. *Gefasschirurgie.* 2021;25(1):51-60. Available from: <https://www.ncbi.nlm.nih.gov/books/NBK430748/>
13. Corcos O, Nuzzo A. Gastro-intestinal vascular emergencies. *Best Pract Res Clin Gastroenterol.* 2013;27(5):709-25. doi:10.1016/J.BPG.2013.08.006
14. Boley SJ, Brandt LJ, Sammartano RJ. History of mesenteric ischemia. The evolution of a diagnosis and management. *Surg Clin North Am.* 1997;77(2):275-88. doi:10.1016/S0039-6109(05)70548-X
15. Boley SJ, Sprayregan S, Siegelman SS, Veith FJ. Initial results from an aggressive roentgenological and surgical approach to acute mesenteric ischemia. *Surgery.* 1977;82(6):848-55. Available from: <https://pubmed.ncbi.nlm.nih.gov/929375/>
16. White CJ. Chronic mesenteric ischemia: diagnosis and management. *Prog Cardiovasc Dis.* 2011;54(1):36-40. doi:10.1016/J.PCAD.2011.04.005
17. Wyers MC. Acute mesenteric ischemia: diagnostic approach and surgical treatment. *Semin Vasc Surg.* 2010;23(1):9-20. doi:10.1053/J.SEMVASCSURG.2009.12.002
18. Kärkkäinen JM, Lehtimäki TT, Manninen H, Paajanen H. Acute Mesenteric Ischemia Is a More Common Cause than Expected of Acute Abdomen in the Elderly. *J Gastrointest Surg.* 2015;19(8):1407-14. doi:10.1007/S11605-015-2830-3
19. Hmoud B, Singal AK, Kamath PS. Mesenteric venous thrombosis. *J Clin Exp Hepatol.* 2014;4(3):257-63. doi:10.1016/J.JCEH.2014.03.052
20. Biolato M, Miele L, Gasbarrini G, Grieco A. Abdominal angina. *Am J Med Sci.* 2009;338(5):389-95. doi:10.1097/MAJ.0B013E3181A85C3B
21. Kurland B, Brandt LJ, Delany HM. Diagnostic tests for intestinal ischemia. *Surg Clin North Am.* 1992;72(1):85-105. doi:10.1016/S0039-6109(16)45629-X
22. Acosta S, Block T, Björnsson S, Resch T, Björck M, Nilsson T. Diagnostic pitfalls at admission in patients with acute superior mesenteric artery occlusion. *J Emerg Med.* 2012;42(6):635-41. doi:10.1016/J.JEMERMED.2011.03.036
23. Acosta S, Nilsson T. Current status on plasma biomarkers for acute mesenteric ischemia. *J Thromb Thrombolysis.* 2012;33(4):355-61. doi:10.1007/S11239-011-0660-Z
24. Evennett NJ, Petrov MS, Mittal A, Windsor JA. Systematic review and pooled estimates for the diagnostic accuracy of serological markers for intestinal ischemia. *World J Surg.* 2009;33(7):1374-83. doi:10.1007/S00268-009-0074-7
25. Blebea J. Duplex ultrasound criteria for diagnosis of splanchnic artery stenosis or occlusion. *J Vasc Surg.* 1992;16(5):796-7. doi:10.1016/0741-5214(92)90237-3
26. AbuRahma AF, Stone PA, Srivastava M, Dean LS, Keiffer T, Hass SM, et al. Mesenteric/cealic duplex ultrasound interpretation criteria revisited. *J Vasc Surg.* 2012;55(2):428-36. doi:10.1016/J.JVS.2011.08.052
27. Bowersox JC, Zwolak RM, Walsh DB, Schneider JR, Musson A, LaBombard FE, et al. Duplex ultrasonography in the diagnosis of celiac and mesenteric artery occlusive disease. *J Vasc Surg.* 1991;14(6):780-8. doi:10.1067/MVA.1991.33215
28. Hagspiel KD, Flors L, Hanley M, Norton PT. Computed tomography angiography and magnetic resonance angiography imaging of the mesenteric vasculature. *Tech Vasc Interv Radiol.* 2015;18(1):2-13. doi:10.1053/J.TVIR.2014.12.002
29. Oliva IB, Davarpanah AH, Rybicki FJ, Desjardins B, Flamm SD, Francois CJ, et al. ACR Appropriateness Criteria® imaging of mesenteric ischemia. *Abdom Imaging.* 2013;38(4):714-9. doi:10.1007/S00261-012-9975-2
30. Kirkpatrick ID, Kroeker MA, Greenberg HM. Biphasic CT with mesenteric CT angiography in the evaluation of acute mesenteric ischemia: initial experience. *Radiology.* 2003;229(1):91-8. doi:10.1148/RADIOL.2291020991
31. Acosta S, Björnsson S, Ekberg O, Resch T. CT angiography followed by endovascular intervention for acute superior mesenteric artery occlusion does not increase risk of contrast-induced renal failure. *Eur J Vasc Endovasc Surg.* 2010;39(6):726-30. doi:10.1016/J.EJVS.2010.01.017
32. Björnsson S, Resch T, Acosta S. Symptomatic mesenteric atherosclerotic disease-lessons learned from the diagnostic workup. *J Gastrointest Surg.* 2013;17(5):973-80. doi:10.1007/S11605-013-2139-Z
33. Di Minno MN, Milone F, Milone M, Iaccarino V, Venetucci P, Lupoli R, et al. Endovascular Thrombolysis in Acute Mesenteric Vein Thrombosis: a 3-year follow-up with the rate of short and long-term sequelae in 32 patients. *Thromb Res.* 2010;126(4):295-8. doi:10.1016/J.THROMRES.2009.12.015
34. Arthurs ZM, Titus J, Bannazadeh M, Eagleton MJ, Srivastava S, Sarac TP, et al. A comparison of endovascular revascularization with traditional therapy for the treatment of acute mesenteric ischemia. *J Vasc Surg.* 2011;53(3):698-705. doi:10.1016/J.JVS.2010.09.049
35. Meilahn JE, Morris JB, Ceppa EP, Bulkley GB. Effect of prolonged selective intramesenteric arterial vasodilator therapy on intestinal viability after acute segmental mesenteric vascular occlusion. *Ann Surg.* 2001;234(1):107-15. doi:10.1097/0000658-200107000-00016

36. Silvestri L, van Saene HK, Zandstra DF, Marshall JC, Gregori D, Gullo A. Impact of selective decontamination of the digestive tract on multiple organ dysfunction syndrome: systematic review of randomized controlled trials. *Crit Care Med.* 2010;38(5):1370-6. doi:10.1097/CCM.0B013E3181D9DB8C
37. Nuzzo A, Maggiori L, Paugam-Burtz C, Cazals-Hatem D, Ronot M, Huguët A, et al. Oral Antibiotics Reduce Intestinal Necrosis in Acute Mesenteric Ischemia: A Prospective Cohort Study. *Am J Gastroenterol.* 2019;114(2):348-51. doi:10.1038/S41395-018-0389-9
38. Gatt M, Reddy BS, MacFie J. Review article: bacterial translocation in the critically ill--evidence and methods of prevention. *Aliment Pharmacol Ther.* 2007;25(7):741-57. doi:10.1111/J.1365-2036.2006.03174.X
39. Corcos O, Castier Y, Sibert A, Gaujoux S, Ronot M, Joly F, et al. Effects of a multimodal management strategy for acute mesenteric ischemia on survival and intestinal failure. *Clin Gastroenterol Hepatol.* 2013;11(2):158-65. doi:10.1016/J.CGH.2012.10.027
40. Beaulieu RJ, Arnaoutakis KD, Abularrage CJ, Efron DT, Schneider E, Black III JH. Comparison of open and endovascular treatment of acute mesenteric ischemia. *J Vasc Surg.* 2014;59(1):159-64. doi:10.1016/J.JVS.2013.06.084
41. Schoots IG, Levi MM, Reekers JA, Lameris JS, van Gulik TM. Thrombolytic therapy for acute superior mesenteric artery occlusion. *J Vasc Interv Radiol.* 2005;16(3):317-29. doi:10.1097/01.RVI.0000141719.24321.0B
42. Schermerhorn ML, Giles KA, Hamdan AD, Wyers MC, Pomposelli FB. Mesenteric revascularization: management and outcomes in the United States, 1988-2006. *J Vasc Surg.* 2009;50(2):341-8. doi:10.1016/J.JVS.2009.03.004
43. Björnsson S, Björck M, Block T, Resch T, Acosta S. Thrombolysis for acute occlusion of the superior mesenteric artery. *J Vasc Surg.* 2011;54(6):1734-42. doi:10.1016/J.JVS.2011.07.054
44. Plumereau F, Mucci S, Le Naoures P, Finel JB, Hamy A. Acute mesenteric ischemia of arterial origin: importance of early revascularization. *J Visc Surg.* 2015;152(1):16-21. doi:10.1016/J.JVISCURG.2014.11.001
45. Kougiass P, Lau D, El Sayed HF, Zhou W, Huynh TT, Lin PH. Determinants of mortality and treatment outcome following surgical interventions for acute mesenteric ischemia. *J Vasc Surg.* 2007;46(3):467-74. doi:10.1016/J.JVS.2007.04.045
46. Acosta-Merida MA, Marchena-Gomez J, Hemmersbach-Miller M, Roque-Castellano C, Hernandez-Romero JM. Identification of risk factors for perioperative mortality in acute mesenteric ischemia. *World J Surg.* 2006;30(8):1579-85. doi:10.1007/S00268-005-0560-5
47. Sullivan TM, Oderich GS, Malgor RD, Ricotta II JJ. Open and endovascular revascularization for chronic mesenteric ischemia: tabular review of the literature. *Ann Vasc Surg.* 2009;23(5):700-12. doi:10.1016/J.AVSG.2009.03.002
48. Cai W, Li X, Shu C, Qiu J, Fang K, Li M, et al. Comparison of clinical outcomes of endovascular versus open revascularization for chronic mesenteric ischemia: a meta-analysis. *Ann Vasc Surg.* 2015;29(5):934-40. doi:10.1016/J.AVSG.2015.01.010
49. Atkins MD, Kwolek CJ, LaMuraglia GM, Brewster DC, Chung TK, Cambria RP. Surgical revascularization versus endovascular therapy for chronic mesenteric ischemia: a comparative experience. *J Vasc Surg.* 2007;45(6):1162-71. doi:10.1016/J.JVS.2007.01.067
50. Tallarita T, Oderich GS, Macedo TA, Gloviczki P, Misra S, Duncan AA, et al. Reinterventions for stent restenosis in patients treated for atherosclerotic mesenteric artery disease. *J Vasc Surg.* 2011;54(5):1422-9. doi:10.1016/J.JVS.2011.06.002
51. Van Petersen AS, Kolkman JJ, Beuk RJ, Huisman AB, Doelman CJ, Geelkerken RH. Open or percutaneous revascularization for chronic splanchnic syndrome. *J Vasc Surg.* 2010;51(5):1309-16. doi:10.1016/J.JVS.2009.12.064
52. Cho JS, Carr JA, Jacobsen G, Shepard AD, Nypaver TJ, Reddy DJ. Long-term outcome after mesenteric artery reconstruction: a 37-year experience. *J Vasc Surg.* 2002;35(3):453-60. doi:10.1067/MVA.2002.118593
53. Kruger AJ, Walker PJ, Foster WJ, Jenkins JS, Boyne NS, Jenkins J. Open surgery for atherosclerotic chronic mesenteric ischemia. *J Vasc Surg.* 2007;46(5):941-5. doi:10.1016/J.JVS.2007.06.036
54. Rhee RY, Gloviczki P, Mendonca CT, Petterson TM, Serry RD, Sarr MG, et al. Mesenteric venous thrombosis: still a lethal disease in the 1990s. *J Vasc Surg.* 1994;20(5):688-97. doi:10.1016/S0741-5214(94)70155-5
55. Takahashi N, Kuroki K, Yanaga K. Percutaneous transhepatic mechanical thrombectomy for acute mesenteric venous thrombosis. *J Endovasc Ther.* 2005;12(4):508-11. doi:10.1583/04-1335MR.1
56. Hirsch AT, Haskal ZJ, Hertzler NR, Bakal CW, Creager MA, Halperin JL, et al. ACC/AHA 2005 Practice Guidelines for the management of patients with peripheral arterial disease (lower extremity, renal, mesenteric, and abdominal aortic): a collaborative report from the American Association for Vascular Surgery/Society for Vascular Surgery, Society for Cardiovascular Angiography and Interventions, Society for Vascular Medicine and Biology, Society of Interventional Radiology, and the ACC/AHA Task Force on Practice Guidelines (Writing Committee to Develop Guidelines for the Management of Patients with Peripheral Arterial Disease). *Circulation.* 2006;113(11):e463-e654. doi:10.1161/CIRCULATIONAHA.106.174526
57. Jia Z, Jiang G, Tian F, Zhao J, Li S, Wang K, et al. Early endovascular treatment of superior mesenteric occlusion secondary to thromboemboli. *Eur J Vasc Endovasc Surg.* 2014;47(2):196-203. doi:10.1016/J.EJVS.2013.09.025