



ASSESSMENT OF SURGERY COMPLICATIONS TO REPAIR POST BURN SCAR CONTRACTURE OF NECK WITH CERVICODELTOID FLAP

Ali Enshaei¹, Naser Khalaji^{*2}

1. *Burn Center, Imam Khomeini Hospital, Urmia University of Medical Sciences, Urmia, Iran*
2. *Physiology department, Medicine Faculty, Urmia University of Medical Sciences, Urmia, Iran*

ARTICLE INFO

Received:

03th Jun 2017

Accepted:

29th Nov 2017

Available online:

14th Dec 2017

Keywords: *Burn, Cervicodeltoid flap, Contracture, Scar*

ABSTRACT

Background: Neck scar contracture is an important complication of burns and still represents a major challenge for plastic surgeons. This study was aimed to assess the surgical procedures used to reconstruction of the neck scar contracture and their complications by cervicodeltoid flap in Urmia, Iran, 2015.

Methods: This observational descriptive study was conducted on 25 patients (7 males, 18 females) with a mean age of 31.80 years who had post burn scar contracture of neck. These patients undergone operation under general anesthesia then scar released and cervicodeltoid flap was performed.

Results: In all of the patients, successful release of the contractures was achieved without any complication or recurrence of the contractures in the follow-up period. The most complications of flap included hematoma in 3 patients (12%), seroma in 2 patients (8%), infection in zero patient (0%), flap loss in zero patient (0%) and suture dehiscence in zero patient (0%), ischemia and necrosis of end flap in 5 patients (20%).

Conclusion: According to the results, in the application of cervicodeltoid flap, there is no necessary to have skin grafts for the area which the flap is taken, and the flap will solve the problem of dynamic constraint depending on the patient's condition including the age, location and expanse of the scar in neck and thus our results showed less side effects.

Copyright © 2013 - All Rights Reserved - Pharmacophore

To Cite This Article: Ali Enshaei, Naser Khalaji, (2017), "assessment of surgery complications to repair post burn scar contracture of neck with cervicodeltoid flap", *Pharmacophore*, 8(6S), e-1173226.

Introduction

Burn is a serious injury in the world and burn wound healing is a major problem [1, 2]. Burn injuries can be a major source of mortality and morbidity from trauma in many parts of the world [3]. Moreover, burn is the most expensive traumatic injury, due to long hospitalization, rehabilitation and costly treatment of scar and wound [4]. Organ functions may be impaired in the acute phase of burn and in severely burned patients, there are functional and aesthetic late complications [5]. One of the most complications of post burn is scar [6]. Scar contractures cause many problems such as aesthetic, psychological, functional and social problems and neck contractures lead to deformity of the lower lip, chin, neck and chest [7].

Besides the effects of post burn neck contractures on the movements of the neck, they also can affect the function of the lower face and result in possible tracheal alteration. Because of functional and cosmetic problems as well as economic and psychosocial side effects due to these contractures, surgical correction is generally recommended, especially in children in whom they can cause growth imbalance in the head and neck area [8]. Tissue expanders, bioengineered dermal substitutes, local or free flaps, and autologous skin grafting are the standard treatments of neck contracture [9]. Neck scar contracture is

an important complication of burns and still represents a major challenge for plastic surgeons [10-12]. There are many methods to treat neck contractures, including Z-plasties, split-thickness skin grafts, full-thickness skin grafts, local or pedicle skin flaps, pedicle or free musculocutaneous flaps, perforator flaps, super thin flaps and free cutaneous flaps [10, 13, 14]. The aforementioned techniques often imply multiple surgeries and increasing morbidity and usually offer poor aesthetic and functional outcomes [15]. The purpose of this study was to evaluate the surgical procedures for reconstruction of the neck using cervicodeltoid flap.

Materials and Methods

This observational descriptive study was done in the Imam Khomeini hospital of Urmia, Iran from august 2010 to august 2015. Twenty five patients were included in this study (7 males, 18 females). Their ages ranged from 18 to 45 years with a mean age of 31.80 years. All presented with post-burn scar contracture needed surgical release and they were suitable candidates for cervicodeltoid flap (Figure 1).

After administration of patients in the burns unit, they were prepared for operation. The study was performed according to the protocol of the ethical guidelines of the declaration of Helsinki.

The surgical technique was performed under general anesthesia. After deep anesthesia, the entire scar contracture of neck was removed by a scalpel, fibrous tissues were removed and after hemostasis with bipolar cauterization, they were prepared for flaps (Figure 2). The result from the release of scar tissue in the cervical region was good.

The defect was created then grafted with cervicodeltoid flap according the size and length of contracture defect. Because flap size was determined according to the recipient site, and the flap was designed on the deltoid skin and tissue expanders of various kinds, sizes, and shapes were used in relation to the distribution of scar tissue. All expander ports were positioned externally (Figure 3-a).

A vacuum drain was also placed in the site, if necessary. Vacuum drains were used in case of uncertainty about hemostasis or probability of fluid accumulation at the pocket site, for instance due to adjacency to cervical lymph nodes. Then the flap was fixed at its ends with a few sutures. The donor sites were closed directly despite the large dimensions of the flaps (Figure 3-b).

Results

The present study was carried out on 25 patients with cervical post-burn scar contractures. In this study, 18 patients (72%) were female and 7 patients (28%) were male. Reconstruction and Flap of cervical in 20 patients were done unilateral and in 5 patients were used bilateral flap. In all of the patients, successful release of the contractures was achieved without any complication or recurrence of the contractures in the follow-up period. In the follow-up visits one month after operation, in all cases, moderately good skin color was achieved. The functional and aesthetic result was considerably improved by the use of cervicodeltoid flap. The site of operation necrosis was not observed and all flaps were successful. As show in table 1, the most complications of flap included hematoma in 3 patients (12%) which were drained, seroma in 2 patients (8%) which were aspirated, infection in zero patient (0%) which were controlled by dressing and antibiotics, flap loss in zero patient (0%) and suture dehiscence in zero patient (0%) and ischemia and necrosis of end flap in 5 patients (20%). The Ischemia and necrosis of the end flap was managed conservatively and recovered completely. This complication did not require surgical intervention. In this method, all of the patients were pleased and satisfied.

Table 1. Frequency of surgical satisfaction and complication.

Total Number of Patients		Satisfaction		Flap Ischemia		Hematoma		Seroma		Infection		Flap Necrosis	
N	%	N	%	N	%	N	%	N	%	N	%	N	%
25	100%	25	100%	5	20%	3	12%	2	8%	0	0%	0	0%

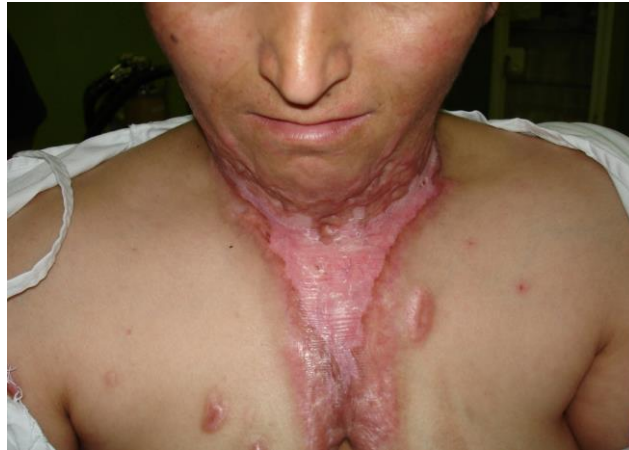

Figure 1. Patient with post-burn scar contracture of the neck

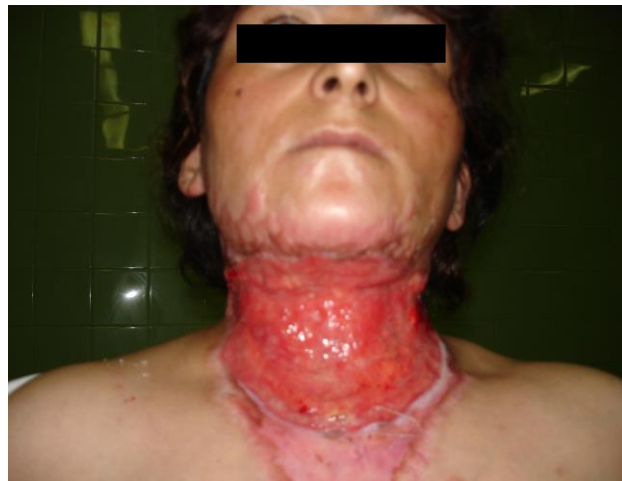

Figure 2. Preoperative view of flap in a case after the contracture release.

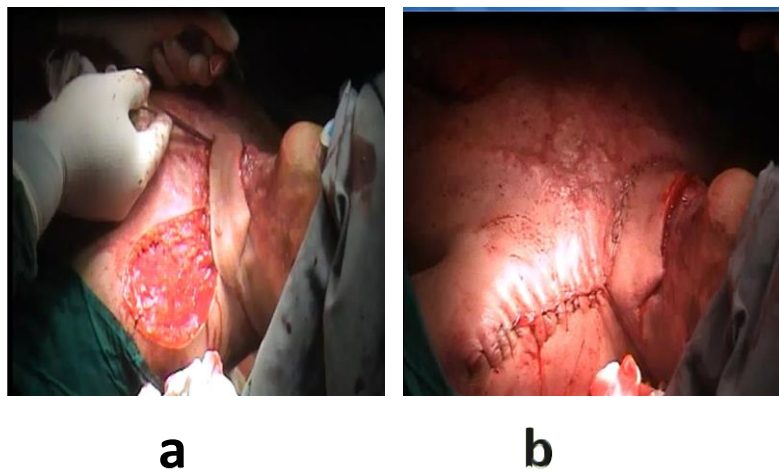


Figure 3. The view of cervicodeltoid flap during operation (a) and after suturing (b).

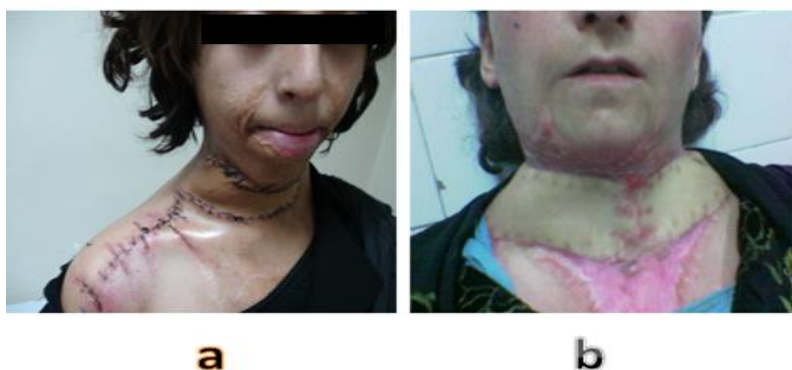

Figure 4. Post-operative view of unilateral (a) and bilateral (b) cervicodeltoid flap

Discussion

Our study reflected the surgical procedure to release post-burn scar contracture of the neck. Neck is a sensitive area in term of both beauty and function. Many functional limitations and beauty abnormalities are seen after post-burn contracture of the neck. Reconstruction of severe deformities and scars in the neck following healing from burns is one of the main challenges of surgeons [16]. Many methods have been supported to reconstruct neck contractures for cosmetic goals [10,13, 14] and all of them have their advantages, disadvantages, and limitations. For example skin graft can cover a wide area after complete scar excision in a single operative procedure, simple, reliable, and safe but recurrence is not common due to secondary skin graft contracture, especially with split thickness skin grafts [2, 17]. The use of local tissue, considering the same color and texture with the injury site is sometimes difficult or impossible to be achieved in burn patients because the local flaps need a sophisticated procedure [18, 19]. Myocutaneous flaps are a good method for reconstruction of severe mentosternal contracture deformities but their bulkiness accompanied with cervical sagging as well as the need to rotate the vascular pedicle of the flap for 180° when using the skin paddle to resurface the neck and reduction of swallowing or speech function limit their use [20-24]. this flap is particularly suitable for repairing post-burn scar contracture of the neck. In addition, this flap has the potential ability to be used as a large free flap [25]. The free flap technique does not always give a good outcome. It is time-consuming and costly. However in the head and neck region, free flaps reconstruct different anatomic structures with good results. Free flaps in head and neck burning can reduce facial muscle movements and lead to neck contours, unnatural face and poor cosmetic aspect (different colour, excessive bulk)[26-28]. We believe that surgical procedures should be scheduled depending on patient status and also on priorities determined by the burn team in collaboration with the patient [29, 30]. Our efforts have focused on choosing the appropriate techniques that at the same time should give functional and cosmetic results.

This research indicated the healing of cervical post-burn scar contracture with cervicodeltoid flap. Skin from the deltoid area is considered a good match for reconstruction of the neck regions and this method is easier to perform. It was first described by Kazanjian and Converse as “in charretera” or acromial flap [31]. We have achieved good results in this research. This flap is easy to perform, with both good functional and as well as color match and aesthetic results. In our experience, all patients were satisfied. There was very low necrosis and infection in sites of operation and all of flaps were successful. This flap does not need any skin graft. In terms of the costs of cervicodeltoid flap in comparison to other surgeries of neck reconstruction is lower costs of hospital admission and the patient’s stayed for shorter time in hospital.

Conclusion

According to the results, in the application of cervicodeltoid flap, there is no necessary to have skin grafts for the area which the flap is taken, and the flap will solve the problem of dynamic constraint depending on the patient’s condition including the age, location and expanse of the scar in neck and thus our results showed less side effects.

Conflict of interest

The authors reported no conflict of interest in this study.

Acknowledgement

The authors would like to thank the staff of operating room of Imam Khomeini Hospital of Urmia and patients participating in this study, especially Amin Abdolazade Fard who was a major contributor in writing the manuscript.

Reference

1. Oladele AO, Olabanji JK. Burns in Nigeria: a review. *Ann Burns Fire Disasters*. 2010;23(3):1207-
2. Motamed S, Jahadi R, Asadi M, H. M. Burn Scar Reconstruction of the Neck with FTSG Obtained from Lower Abdominal Skin. *Acta Medica Iranica*. 2011;49(5):310-3.
3. Forjuoh SN. Burns in low- and middle-income countries: a review of available literature on descriptive epidemiology, risk factors, treatment, and prevention. *Burns*. 2006;32(5):529-37.
4. Sanchez JL, Pereperez SB, Bastida JL, Martinez MM. Cost-utility analysis applied to the treatment of burn patients in a specialized center. *Arch Surg*. 2007;142(1):50-7; discussion 7.
5. Spanholtz TA, Theodorou P, Amini P, Spilker G. Severe burn injuries: acute and long-term treatment. *Dtsch Arztebl Int*. 2009;106(38):607-13.
6. Kwan P, Desmouliere A, Tredget E. Molecular and cellular basis of hypertrophic scarring. In: Herndon D, editor. *Total burn care 3rd ed*. Philadelphia: Saunders Elsevier; 2012. p. 495-505.
7. Seo DK, Kym D, Hur J. Management of neck contractures by single-stage dermal substitutes and skin grafting in extensive burn patients. *Ann Surg Treat Res*. 2014;87(5):253-9.
8. Mody NB, Bankar SS, Patil A. Post burn contracture neck: clinical profile and management. *J Clin Diagn Res*. 2014;8(10):NC12-7.
9. Wetzig T, Gebhardt C, Simon JC. New indications for artificial collagen-elastin matrices? Covering exposed tendons. *Dermatology*. 2009;219(3):272-3.
10. Karacaoglan N, A. U. Reconstruction of post-burn scar contracture of the neck by expanded skin flap. *Burns*. 1994;20:547.
11. Grevious MA, Paulius K, Gottlieb LJ. Burn scar contractures of the pediatric neck. *J Craniofac Surg*. 2008;19(4):1010-5.
12. Kumar B, Vadaje K, Sethi S, Singh A. Failed intubating laryngeal mask airway-guided blind endotracheal intubation in a severe postburn contracted neck patient. *Acta Anaesthesiol Belg*. 2011;62(2):95-9.
13. Hyakusoku H, Gao JH. The "super-thin" flap. *Br J Plast Surg*. 1994;47(7):457-64.
14. Ogawa R, Hyakusoku H, Murakami M. Color Doppler ultrasonography in the planning of microvascular augmented "super-thin" flaps. *Plast Reconstr Surg*. 2003;112(3):822-8.
15. Latifoglu O, Ayhan S, Atabay K. Total face reconstruction: skin graft versus free flap. *Plast Reconstr Surg*. 1999;103(3):1076-8.
16. Motamed S, Kalantar A, S. M. Expanded occipito-pectoral flap for reconstruction of burned cervical contracture. *Burns*. 2003;29:842-4.
17. Pallua N, E. D. Post-burn head and neck reconstruction in children with the fasciocutaneous supraclavicular artery island flap. *Ann Plast Surg*. 2008;60:276.
18. Hallock GG. The role of local fasciocutaneous flaps in total burn wound management. *Plast Reconstr Surg*. 1992;90(4):629-35.
19. Motamed S, Mousavizadeh SM, Niazi F, Khajouei Kermani H, Saberi A, Motamed H. Lateral lower face and neck contouring following burn injury. *Acta Med Iran*. 2015;53(4):225-30.
20. Wilson IF, Lokeh A, Schubert W, Benjamin CI. Latissimus dorsi myocutaneous flap reconstruction of neck and axillary burn contractures. *Plast Reconstr Surg*. 2000;105(1):27-33.
21. Ulrich D, Fuchs P, N. P. Pre-expanded vertical trapezius musculocutaneous flap for reconstruction of a severe neck contracture after burn injury. *J Burn Care Res*. 2008;29:386.
22. Adams WP, Jr., Lipschitz AH, Ansari M, Kenkel JM, Rohrich RJ. Functional donor site morbidity following latissimus dorsi muscle flap transfer. *Ann Plast Surg*. 2004;53(1):6-11.
23. Kruse AL, Luebbbers HT, Obwegeser JA, Bredell M, Gratz KW. Evaluation of the pectoralis major flap for reconstructive head and neck surgery. *Head Neck Oncol*. 2011;3:12.
24. Rajan R, Reddy S, R. R. the pectoral is major myocutaneous flap in head and neck reconstruction. *IJO&HNS*. 1997;49(2):368-73.
25. Wang J. [Extra-long trapezius myocutaneous fascia flap for repairing burn scar contracture of the neck]. *Zhongguo Yi Xue Ke Xue Yuan Xue Bao*. 1992;14(5):317-9.
26. Turner AJ, Parkhouse N. Revisiting the reconstructive ladder. *Plast Reconstr Surg*. 2006;118(1):267-8.
27. Adant JP, Bluth F, D. J. Reconstruction of neck burns. A long-term comparative study between skin grafts, skin expansion and free flaps. *Acta Chir Belg*. 1998;98(1):5-9.

28. Giordano L, Bondi S, Toma S, Biafora M. Versatility of the supraclavicular pedicle flap in head and neck reconstruction. *Acta Otorhinolaryngol Ital.* 2014;34(6):394-8.
29. Robson MC, Barnett RA, Leitch IOW, PG. H. Prevention and treatment of post-burn scars and contracture. *World J Surg.* 1992;16:87-96.
30. Robson MC, DJ. S. Reconstruction of the burned face, neck and scalp. In: J.A. B, editor. *The Art and Science of Burn Care.* Rockville: Aspen Publishers; 1987.
31. Kazanjian VH, JM. C. *The Surgical treatment of facial injuries.* Baltimore: Williams & Wilkins; 1949.