



COMPARATIVE HISTOLOGY OF LIVER IN COTURNIX COTURNIX AND PYCNONOTUS LEUCOTIS

Fatemeh soltani sarvestani

Department Biology, payame noor university, 19395-4697 Tehran, I.R. of Iran.

ARTICLE INFO

Received:

03th Jun 2017

Accepted:

29th Nov 2017

Available online:

14th Dec 2017

Keywords: *hiver, Histology, Herbivore, Omnivore*

ABSTRACT

This study was carried out to compare the liver histology of coturnix coturnix as omnivore bird and pycnonotus leucotis as herbivore bird. coturnix coturnix was provided from Ghatre tala ltd, farmed in cage and fed with insects, snails, grass, worm and other things may provide from natural environment but pycnonotus leucotis farmed in cage & fed with grapes, apple, palm and other fruits. 5 adult of both specimens were killed by decapitation, birds were dissected and 0.5×0.5 fragments of liver tissue fixed in %10 formalin solution after dehydration and embedding in paraffin. 7μ sections were provided and stained with hematoxylin eosin routine method. slides observed with light microscope. results showed that in both specimen livers have hepatocytes with large nucleus, in herbivore bird organelles of the cell was clear but in omnivore bird organelles weren't clear, but omnivore form had more fatty cell in liver tissue, kupffer cell wasn't seen in both specimens.

Copyright © 2013 - All Rights Reserved - Pharmacophore

To Cite This Article: Fatemeh soltani sarvestani, (2017), "comparative histology of liver in coturnix coturnix and pycnonotus leucotis", *Pharmacophore*, 8(6S), e-1173429.

Introduction

Liver is the greatest gland in avian alimentary tract, which, have substantial role in carbohydrates, proteins & lipids metabolism, drugs detoxification, vitellin synthesis, and even bile secretion. And regulates the hemostasis of body metabolites [1]. Hence, structure, function and especially histology of liver is noticeable in many disease & pathologic problems. [2, 3, 4]. Especially, fatty liver is described in variety of birds. [5, 6]. Which, suggested, nutritional diet and metabolic factors have great role in this problem, Gullvage & Collages, 1978, traced mercury in the liver of Japanese Quail, which, fed in their food diets as methyl mercury and found this substance in their eggs[7]. Reisinger, 2005 presented, use of carbendazim as dressed seed in the diet of Japanese Quail for 8 week, and detected carbendazim residue can find in liver & pectoral muscle tissues if used in high dosage[8]. Dietary tryptophan deficiency in different tissues of broilers chicken revealed, it can induce lesion of mandibular rhamphotheca [9]). This study, has carried out to compare, liver histology of Coturnix coturnix fed with different diet as omnivore bird and Pycnonotus leucotis fed just by fruits as herbivore bird.

Material & methods

Housing

2- days male & female Coturnix coturnix was provided from Ghatre tala company, placed in cage individually with temperature 28°C and 14 hour photoperiod and access to water fed with different food diet such as insects, snails, chopped vegetables and green grass and other things may be provided from natural environment and pycnonotus leucotis was purchased from bird gardens near Shiraz, Fars province Iran, was placed in cage individually and fed with just fruits such as palm, apple & grapes and other fruit.

Sampling

At 5th week, 10 specimen of both group, selected randomly, after decapitation, tissue samples of liver in both specimen, dissected & washed by phosphate buffered saline and fixed in 10 percent formalin solution.

Samples dehydrated in series of ethanol solutions from %50 to absolute ethanol. Tissue samples embedded in paraffin and 7 μ sections were provided and stained with hematoxylin Eosin routine methods. Micrographs were taken with video camera connected to microscope (Olympus, Japan).

Results & Discussions

Liver composed of right and left lobe which join together at midline of anterior area. In most of avian species, right lobe is larger than left lobe especially, in galliforms [10, 11]. In Passeriformes species right lobe is divided to some sections. Since liver, hasn't any serosa layer and fatty tissue, exposed when body cavity dissected.

In both specimen of this study, liver were dark color and blobbed which drained to duodenum with two different bile duct.

Intera hepatic branches of blood vessel in mammals and avian is fundamentally similar. Hepatic portal collected blood, from the gastro splenic vein, gastro duodenal vein and superior mesenteric veins. The terminal branches of hepatic vein and portal vein connected to sinusoids networks. [12,13] Construction of avian liver is basically as other vertebrates, in which, termed, morallium [14]. Lobular arrangement in avian liver, due to poor connective tissue around lobular out line, wasn't clear, since, it wasn't observed in both specimen of this study. Hepatocytes of avian liver arranged as anastomosing sheets. These sheet in mammalian liver are one cell thick but in birds, it may composed of one cell thick or two cell thick. Single cell thickness sheets, the bile canaliculi are made between two cells and forming enclosing network around individual cell. Whereas, in two cell thickness sheets, the bile canaliculi are made between three, four or five adjacent cells and don't form enclosing network around the cells. However, it forms between two layers of sheets. [13,17]. In this study, in *Coturnix coturnix*, thickness of sheets were two cell but in *Pycnonotus leucotis*, just, thickness of sheets were just one cell. (Figure 1) (Figure 2).

Elias, stated that, one cell thickness sheets observed in mammalian species, provides a more physiological efficiency by increasing contact between the cell & blood [14]. However, variation in thickness of sheets between the birds, as well as other characteristic such as average heart rate, composition of muscle tissue, adapted them for occupying different ecological niches and evolved under force of natural selection [15, 16, 17].

In *Coturnix coturnix* liver transvers section, composed of cords of 4-6 hepatocytes arranged radially around a central canaliculi. Hepatocytes had round generally large nucleus. Near to bile canaliculus or prinosoidal surface. The most numerous organelle in hepatocytes were mitochondria, however, other organelles, observed too. But, in *Pycnonotus leucotis*, liver transvers section, composed of just, one cell sheets with large hepatocytes which had large nucleus and clear mitochondria and other organelle (Figure 1) (figure 2). RER occupied most of cytoplasm in some hepatocytes However, it wasn't clear for all hepatocytes.

In overall, appearance of hepatocytes in both of specimen were similar to domestic fowl (Soltani, 2016). But in *Coturnix coturnix*, the quantity of fat droplet in cytoplasm of hepatocytes was more. [17] contributed this to the formation of yolk lipoproteins. However, it's difficult to diagnosis, this droplet is due to impaired fat metabolism or formation of yolk lipoproteins.

In *Coturnix coturnix*, also observed, fat cell, even, with variation of lipid droplet in cytoplasm and size. But these cells wasn't observed in *Pycnonotus leucotis*, which, refers to variation in food diets, since, *Pycnonotus leucotis* just utilized fruits. In both specimen, didn't observed Kupffer cell and endothelial cell.

References

1. Duke, G. 1986. Alimentary Canal; secretion and digestion, special digestive functions and absorption. In: Sturkie (ed). Avian physiology. New York: Springer-Verlag. 286-302
2. Bryden, W. R., Cumming. 1980., Observation on the liver of chicken following Afla toxin B, Ingestion, Avian pathology, 531-556
3. Wadsworth, P. D. M., Jonse, and Pugsby, S.L. 1984. Fatty liver in birds at the zoological society of London, Avian pathology. 13, 231- 239
4. Jaensch, S. M., L., Cullen and Raidall, S. 2000. Assessment of liver function in chickens using galactose and Indocyanin green clearance, Avian pathology. 29, 100- 116.
5. Amall, L. and Keymer, I. F. 1975. Bird disease. London: Baillere Tindall. P: 245
6. Minsky, L. and Petrak, M. L. 1982. Disease of digestive system. In: Disease of cage and Aviary Birds. P:444
7. Gullvage, B. M. J. P., Agda land Eskeland, B. 1978. A fine structural study of liver, (littoral) cells of methymercury fed Japanese Quail (*Coturnix coturnix japonica*). Acta pharmacol. et toxicol. 43, 93-98
8. Reisinger, K. J. Szigeti and Varnagy, L. 2005. Determination of carbendazim Residues in the eggs. Liver and pectoral muscle of Japanese quail (*Coturnix coturnix japonica*) 2006. Acta veterinaria Hungarica. 54, 1, 127- 133.
9. Monroe, A. D. K., S., Latimer, G. M., Pesti. And Bakalli, R. I. 2003., pathology and histology of Dietary tryptophan Deficiency in Broiler chicks. Avian disease, 47 (4): 1393- 1398
10. Gould, W. 1992. Liver disease in psittacines. Current veterinary therapy X1 small animal practice. Philadelphia: W. B. Saunders, 1145-1150
11. Hill, K. J. 1977. The physiology of alimentary tract, in physiology and Biochemistry of the Domestic fowl (Ed) Bell, D. J. Freeman, B. M. Vol. 1. London and New York: Academic press

12. Akster, A. R. 1967. Renal portal shunts in the kidney of the domestic fowl. J. Anat. 101: 565- 594.
13. Elias, H. and Bengelsdorf, H. 1952. The structure of liver of vertebrates. Acta anat. 14- 297- 337.
14. Elias, H. 1952. Geometry of cell shape and adaptive evolution of the liver. J, morph. 91: 362- 388.
15. Mayer, E. and Amadon, D. 1951. A classification of recent birds. Amer. Mus. Novitates No. 1946
16. Odum, E. 1945. The heart rate of small birds. Science, 101, 2615: 153-154
17. -Purton, M. D., 1969. Structure and ultrastructure of the liver in the domestic fowl, Gallus gallus, j, Zool., Lond, 159: 273- ۲۸۲

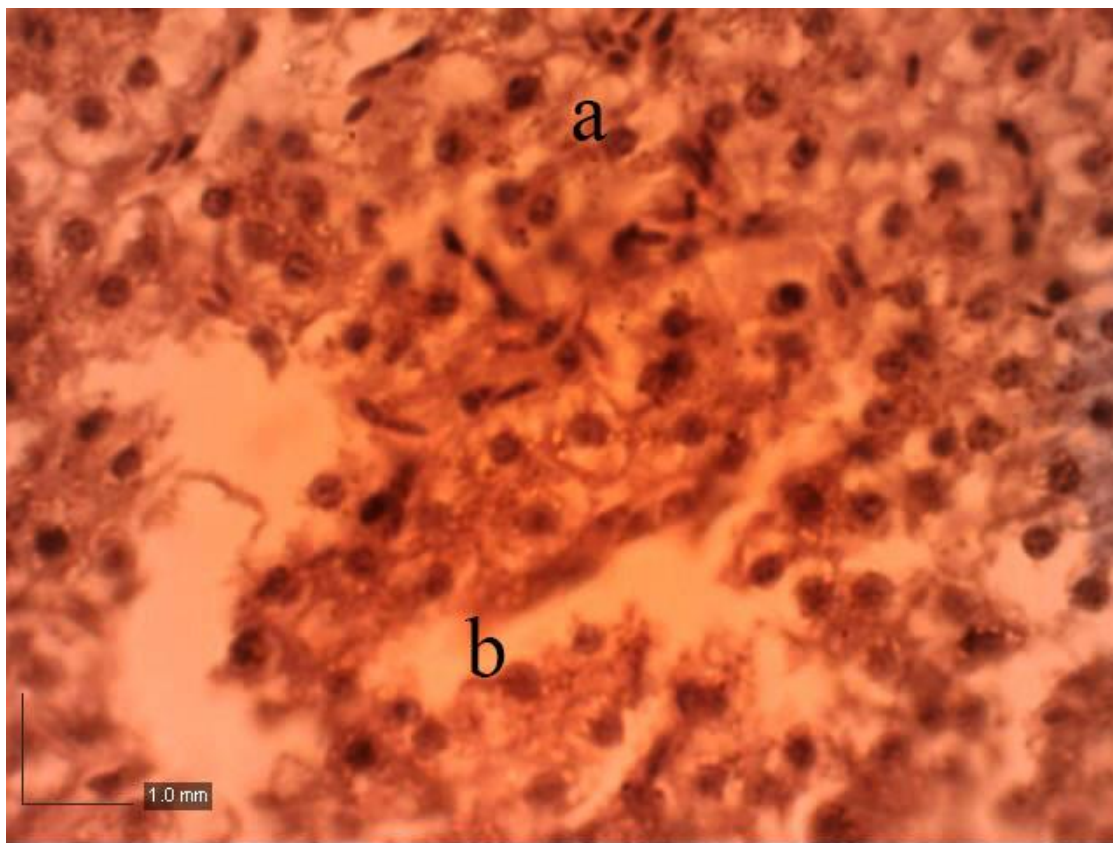


Figure:1 Pycnonotus leucotis. liver 40x a:hepatocytes b:sinosoids scale:1.0mm

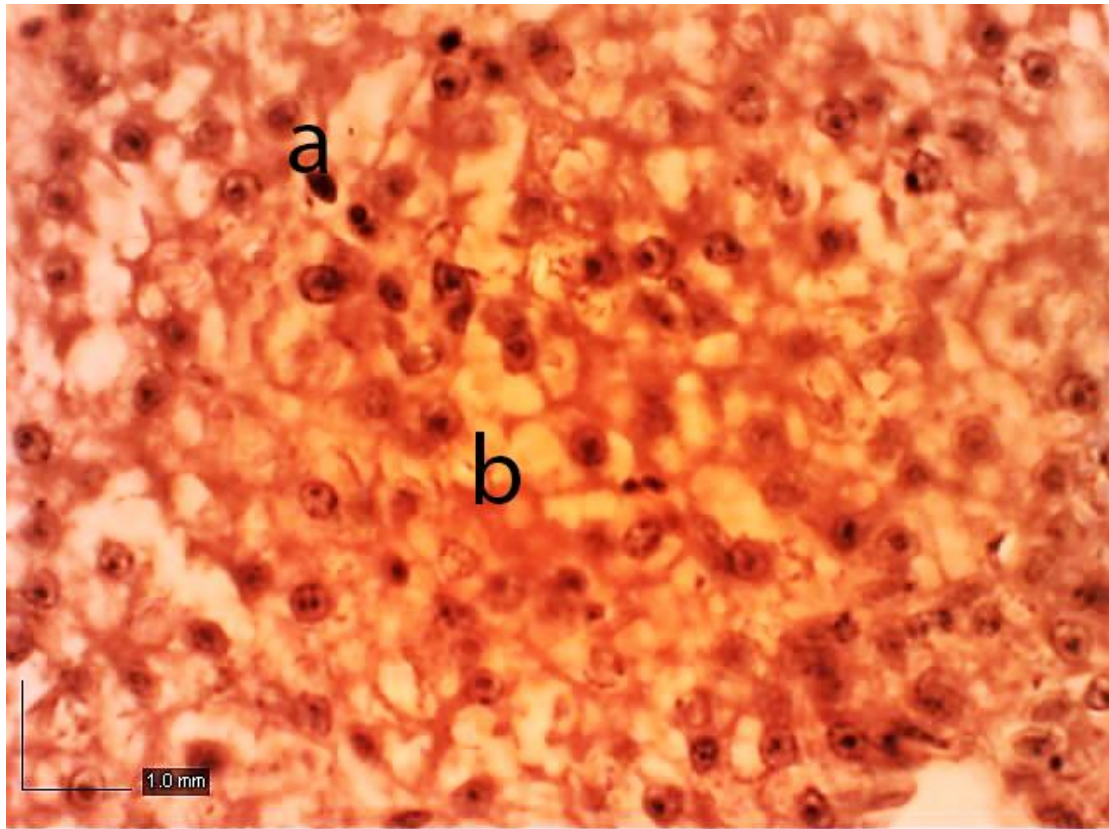


Figure:2 *Coturnix coturnix* liver:40x a:hepatocytes b:fat cell scale:1.0mm